

Insert to

## MIGS RESOURCE CENTER



*This new MIGS Resource Center is a one-stop site for all things related to microinvasive glaucoma surgery (MIGS). These procedures provide an opportunity to improve IOP control in a safer fashion than with traditional glaucoma surgery such as trabeculectomy. Another goal of MIGS is to reduce the complexity of drug regimens. Yet, a strategy that is gaining popularity is to employ safe glaucoma surgery utilizing MIGS and couple that with the best of pharmaceuticals, the so-called “MIGS and meds” approach. So, while MIGS surgery hopes to reduce the need for medications, a reasonable, more realistic medication schedule is often perfectly acceptable to enhance the efficacy of these very safe, modestly effective procedures.*

*Like many advances in medicine, the MIGS movement has occurred slowly. However, currently, advances are evolving rapidly in each of the different segments of MIGS surgery. Make sure to check in on the MIGS Resource Center periodically for updates on US Food and Drug Administration (FDA) approvals or data from head-to-head comparative trials with various MIGS technologies. We will keep you updated on these rapid developments.*

*In our inaugural piece, we speak with Steven D. Vold, MD, of Vold Vision in Fayetteville, Arkansas. Dr. Vold is an award-winning cataract surgeon specializing in the diagnosis and management of patients with glaucoma. Dr. Vold is one of the most prolific investigators in the various MIGS trials, including the COMPASS study. During our discussion, we talk about how to integrate the MIGS devices into our armamentarium and the general landscape of glaucoma surgery.*



—Thomas W. Samuelson, MD

Go to [eyetube.net/resources/migs-education/](http://eyetube.net/resources/migs-education/) for the MIGS Resource Center

Editorially Independent Content Supported With Advertising by



# THE CURRENT LANDSCAPE OF MIGS DEVICES FOR GLAUCOMA MANAGEMENT

Two respected surgeons discuss how to integrate MIGS devices into our armamentarium.

**Thomas W. Samuelson, MD:** We know phacoemulsification helps most patients with glaucoma, although that idea was controversial in the past.

**Steven D. Vold, MD:** Cataract surgery is a very helpful procedure for glaucoma, especially in patients with a pupillary block. We also know, based on clinical data, that the higher the IOP is when you start cataract surgery, the greater the IOP drop will be.<sup>1,2</sup>

**Dr. Samuelson:** To me, cataract surgery in patients with glaucoma lays the foundation for safe, additive procedures. Canal surgery, either through a canal device or canal ablation, has become a popular method of managing glaucoma (Table 1). What options do you employ?

**Dr. Vold:** Trabecular bypass is a great place to start. The patients who do well with angle surgery include those without

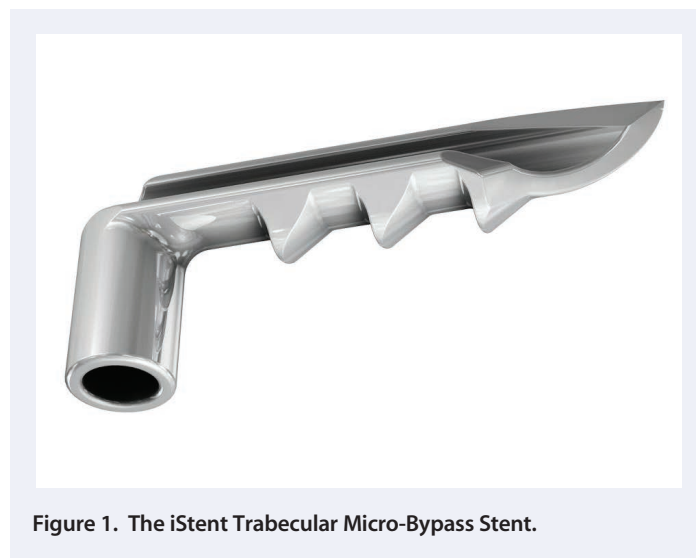


Figure 1. The iStent Trabecular Micro-Bypass Stent.

TABLE 1. COMPARISON OF MIGS OUTFLOW PATHWAYS

	SUBCONJUNCTIVAL	SCHLEMM CANAL	SUPRACILIARY
<b>IOP Lowering</b>	More potent	Low to Moderate	Moderate
<b>Risk</b>	Slightly more	Lowest risk	Low
<b>Ease of Use</b>	Somewhat straightforward to perform Requires Gonio view	Somewhat more difficult Requires Gonio view	Straightforward to perform Requires Gonio view
<b>Potential Issues</b>	<ul style="list-style-type: none"> <li>• Bleb issues</li> <li>• Episcleral healing</li> <li>• Hypotony</li> </ul>	<ul style="list-style-type: none"> <li>• Uncertainty of placement</li> <li>• EVP floor</li> <li>• Distal outflow status</li> </ul>	<ul style="list-style-type: none"> <li>• Proper placement</li> <li>• Choroidal space issues</li> <li>• Fibrosis in SCS</li> </ul>
<b>Other Features</b>	Familiarity Ability to modulate postoperative healing	Physiologic Titratable	Potentially lowers IOP below EVP

Courtesy of Ike K. Ahmed, MD, Steven D. Vold, MD, and Thomas W. Samuelson, MD





## CyPass® Micro-Stent

### IMPORTANT PRODUCT INFORMATION

**CAUTION: FEDERAL (USA) LAW RESTRICTS THIS DEVICE TO SALE BY OR ON THE ORDER OF A PHYSICIAN.**

**INDICATION:** The CyPass® Micro-Stent is indicated for use in conjunction with cataract surgery for the reduction of intraocular pressure (IOP) in adult patients with mild to moderate primary open-angle glaucoma (POAG).

**CONTRAINDICATIONS:** Use of the CyPass Micro-Stent is contraindicated in the following circumstances or conditions: (1) in eyes with angle-closure glaucoma; and (2) in eyes with traumatic, malignant, uveitic, or neovascular glaucoma or discernible congenital anomalies of the anterior chamber angle.

**MRI INFORMATION:** The CyPass Micro-Stent is magnetic resonance (MR) Safe: the implant is constructed of polyimide material, a non-conducting, non-metallic, non-magnetic polymer that poses no known hazards in all magnetic resonance imaging environments.

**WARNINGS:** Gonioscopy should be performed prior to surgery to exclude peripheral anterior synechiae (PAS), rubeosis, and other angle abnormalities or conditions that would prohibit adequate visualization of the angle that could lead to improper placement of the stent and pose a hazard.

**PRECAUTIONS:** The surgeon should monitor the patient postoperatively for proper maintenance of intraocular pressure. The safety and effectiveness of the CyPass Micro-Stent has not been established as an alternative to the primary treatment of glaucoma with medications, in patients 21 years or younger, in eyes with significant prior trauma, chronic inflammation, eyes with an abnormal anterior segment, eyes with chronic inflammation, eyes with glaucoma associated with vascular disorders, pseudophakic eyes with glaucoma, eyes with uveitic glaucoma, eyes with pseudoexfoliative or pigmentary glaucoma, eyes with other secondary open-angle glaucomas, eyes that have undergone prior incisional glaucoma surgery or cilioablate procedures, eyes with laser trabeculoplasty performed  $\leq$  3 months prior to the surgical screening visit, eyes with unmedicated IOP less than 21 mmHg or greater than 33 mmHg, eyes with medicated IOP greater than 25 mmHg, in the setting of complicated cataract surgery with iatrogenic injury to the anterior or posterior segment, and when implantation is without concomitant cataract surgery with IOL implantation for visually significant cataract. The safety and effectiveness of use of more than a single CyPass Micro-Stent has not been established.

**ADVERSE EVENTS:** In a randomized, multicenter clinical trial comparing cataract surgery with the CyPass Micro-Stent to cataract surgery alone, the most common postoperative adverse events included: BCVA loss of 10 or more letters at 3 months after surgery (8.8% for the CyPass Micro-Stent vs. 15.3% for cataract surgery only); anterior chamber cell and flare requiring steroid treatment 30 or more days after surgery (8.6% vs. 3.8%); worsening of visual field mean deviation by 2.5 or more decibels (6.7% vs. 9.9%); IOP increase of 10 or more mmHg 30 or more days after surgery (4.3% vs. 2.3%); and corneal edema 30 or more days after surgery, or severe in nature (3.5% vs. 1.5%).

**ATTENTION: PLEASE REFER TO THE INSTRUCTIONS FOR A COMPLETE LIST OF CONTRAINDICATIONS, WARNINGS, PRECAUTIONS, AND ADVERSE EVENTS.**

**Alcon** A Novartis Division

© 2017 Novartis 2/17 US-CYP-16-E-5201a

## MIGS RESOURCE CENTER

long-standing disease, those with mild to moderate disease, and those who have not been on drops for long periods of time.

### iStent

**Dr. Vold:** The iStent Trabecular Micro-Bypass Stent (indicated for mild to moderate open-angle glaucoma; Glaukos), for example, produces almost no bleeding in the eye at the end of the procedure, which leads to a fast recovery time for patients.<sup>3</sup> The ab interno device is only 1.0 mm long and 0.33 mm high, making it the smallest device currently available (Figure 1). The initial 2-year study results showed a significantly higher proportion of patients with an IOP of 21 mm Hg or lower who did not need ocular hypotensive medications compared with the control group ( $P = .036$ ).<sup>4</sup>

More recently, Katz et al<sup>5</sup> evaluated a total of 119 patients implanted with the iStent as a standalone procedure in three groups: one stent ( $n = 38$ ), two stents ( $n = 41$ ), or three stents ( $n = 40$ ). Both month 12 IOP reduction  $\geq 20\%$  without



Figure 2. The Trab360.

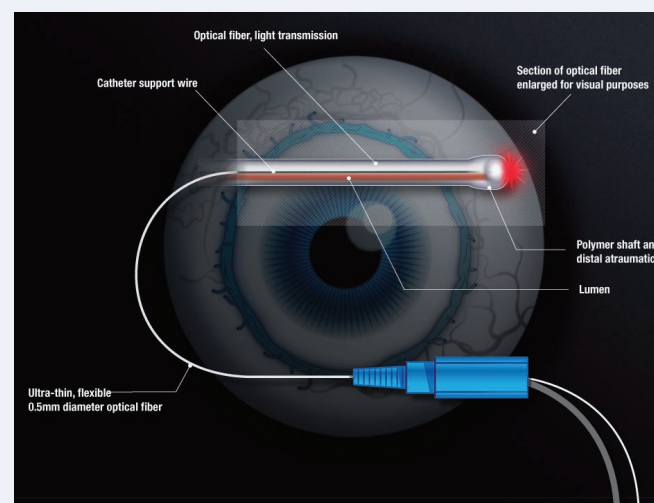


Figure 3. The iTrack microcatheter is used during ABIc.

(Courtesy of Allergan)

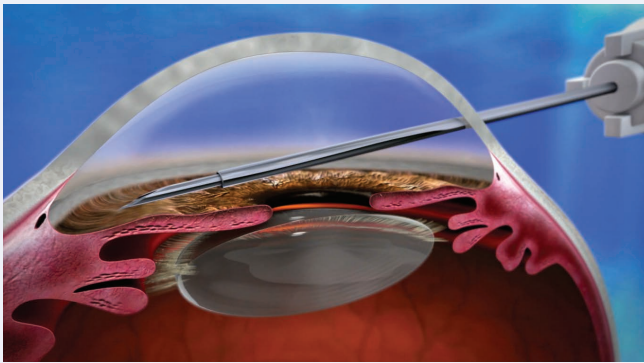


Figure 4. Insertion of the Xen45.

ocular hypotensive medication versus baseline unmedicated IOP and month 12 unmedicated IOP  $\leq 18$  mm Hg were achieved by 89.2%, 90.2%, and 92.1% of one-, two-, and three-stent eyes, respectively.

### Trab360 and Visco360

**Dr. Vold:** Next, there are the Trab360 Trabeculectomy System or the Visco360 Viscosurgical System (Sight Sciences). Retrospective case series for the Trab360 enrolled eyes with primary open-angle glaucoma, and anecdotal reports suggest utility of device in a wide array of glaucomas.<sup>6</sup> Visco 360 is not yet approved by the FDA.

The Trab360 is an implant-free, sutureless, ab interno approach that can be used as a standalone procedure or in combination with cataract surgery (Figure 2). This instrument helps access all of Schlemm canal to manually slice the trabecular meshwork. You can essentially perform a complete circumferential goniotomy from a single, clear corneal incision.

The Visco360 is an implant-free, single-handed, microcather surgical system designed to deliver small amounts of ophthalmic viscosurgical device during surgery. It also employs an ab interno approach, which spares the conjunctiva and sclera from incisions.

### ABiC

**Dr. Vold:** Another ab interno approaches is ab interno canaloplasty (ABiC) using the illuminated iTrack 250A (Ellex), indicated for mild to moderate primary open-angle glaucoma. ABiC flushes out the natural outflow channels while preserving tissue (Figure 3). It also does not require the permanent placement of an implant. It can be used as a standalone procedure or in conjunction with cataract surgery.

ABiC is also the only MIGS procedure that addresses collector channel blockages. Studies show that these blockages may be caused by herniated trabecular meshwork tissue. ABiC's viscodilation opens these herniations to restore full access to collector channel ostia for aqueous outflow.<sup>7,8</sup>

### Hydrus Microstent

**Dr. Vold:** The Hydrus Microstent (Ivantis) is another promising option, although not yet approved by the FDA. The Hydrus is a nitinol-based, Schlemm canal scaffold implanted through the trabecular meshwork using a manual inserter covering about three clock hours. First, it dilates and permanently supports opening approximately three clock hours of the canal. Second, it has a little inlet that stays in the anterior chamber and can increase outflow. It is also a passageway that will go into the canal, giving you three clock hours of support.

I was an investigator in the pivotal Hydrus FDA-approval clinical trial,<sup>9</sup> and have used the device outside the United States as well. It has the potential to carve out a distinct place in our surgical armamentarium.

The Hydrus is currently in late-stage clinical development; Pfeiffer et al<sup>10</sup> reported that 80% of patients implanted with the Hydrus during cataract surgery had a 20% reduction in washed-out IOP compared with only 40% in the cataract surgery-only group.

### Xen45

**Dr. Samuelson:** Most glaucoma surgeons will still need some transscleral options going forward. Since the Xen45 (Allergan) was approved by the FDA in late 2016 for refractory glaucoma; primary open-angle glaucoma, pseudoexfoliative, or pigmentary glaucoma unresponsive to maximum medical therapy.<sup>11</sup> Have you incorporated it into your overall surgical management yet?

**Dr. Vold:** The Xen45 implant (Figure 4) is an ab interno approach,<sup>11</sup> and the InnFocus MicroShunt (formerly MIDI Arrow; Santen) has an ab externo approach.<sup>12</sup> They are similar in many ways to an Ex-Press Glaucoma Filtration Device (Alcon) in reducing postoperative visits and postoperative inflammation. When surgery is done properly, hypotony can also be avoided.

The Xen pivotal trials<sup>11</sup> enrolled patients who had undergone previous glaucoma surgery such as canaloplasty, trabeculectomy, or cyclophotocoagulation. In the clinical trial, Xen45 reduced IOP from a mean medicated baseline of  $25.1 \pm 3.7$  mm Hg to  $15.9 \pm 5.2$  mm Hg at the 12 month visit ( $n = 52$ ). The mean baseline number of IOP-lowering medications was  $3.5 (\pm 1.0)$  versus an average use of  $1.7 (\pm 1.5)$  medications at 12 months.

The great thing about the Xen45 implant is it is just a needle stick. You are inserting the device through a 1.5- to 1.8-mm incision under direct visualization. You are entering the sclera, the area of the nonpigmented trabecular meshwork. It is an elegant procedure when you get it in the right place.

**Dr. Samuelson:** Are there any disadvantages? For example, one of the opportunities a trabeculectomy offers is possible titratability. With the Xen45 you do not have the option to titrate pressure, however, you would likely have far less postoperative care because

you are not using releasable sutures. What are your thoughts on those two different strategies?

**Dr. Vold:** The Xen45 is 45 microns in diameter. You cannot titrate it so much. I think a lot of surgeons are going to be injecting mitomycin C at the time of surgery or before performing surgery. There is going to be a lot of learning there.

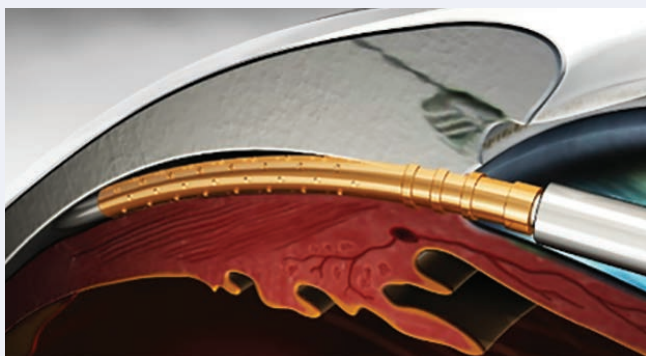
The other thing that is going to be interesting is the use of bleb needling and how we are going to do it. Will we be injecting mitomycin C or 5-fluorouracil? Will we be injecting an ophthalmic viscosurgical device within the bleb at the time of these procedures to potentially improve visualization during bleb needling and hopefully enhance needling outcomes?

Device placement location may play a factor as well. In my experience, there is a possibility of erosion with the Xen45 implant, although much less so when positioned properly. For most surgeons, it is more intuitive to hold the inserter with your dominant hand. Operating in eyes with your nondominant hand (eg, left eyes for right-handed surgeons) can be more challenging. Also, performing surgery on more deep-set eyes can be more technically difficult. However, the promising efficacy and safety profiles may very likely make the extra effort to learn this procedure worthwhile for surgeons.

## CyPass Micro-Stent

**Dr. Samuelson:** You have been heavily involved in the COMPASS trial for the CyPass Micro-Stent (Alcon). What has your experience been with this device so far?

**Dr. Vold:** The CyPass Micro-Stent is for mild to moderate open-angle glaucoma (Figure 5). CyPass device implantation is an intuitive, straightforward procedure, which had positive results from the COMPASS pivotal trial.<sup>13</sup> The trial enrolled 505 eyes in a 3:1 ratio to the CyPass and phacoemulsification (n = 374) or phacoemulsification alone (n = 131); the latter served as the control group. All eyes were observed for 2 years. There was also a washout at the year 1 and 2 follow-up visits



**Figure 5.** CyPass Micro-Stent is implanted in the supraciliary space.

(if patients were on medications), which meant we were able to assess the full potential of the device on its own to lower IOP.<sup>13</sup> The complication profile was similar in the two groups.

A total of 72.5% in the CyPass group and 58.0% in the control group achieved a clinically significant decrease in unmedicated mean diurnal IOP from baseline to 24 months; this between-group difference was statistically significant ( $P = .0030$ ).<sup>13</sup>

The CyPass is inserted into the anterior chamber through the same incisions that were used for the phacoemulsification portion of the surgery. The CyPass is placed in the supraciliary space to take advantage of the uveoscleral outflow and avoid the trabecular meshwork and Schlemm canal. The ab interno approach spares the conjunctiva, which means future filtration surgery (if needed) can remain an option for patients.

We are still waiting on data to determine the role the CyPass might play in people with more advanced disease, those with superior and inferior hemifield visual field loss.

**Dr. Samuelson:** Any pearls to placing a supraciliary stent such as the CyPass?

**Dr. Vold:** Cataract surgeons will find the CyPass to be an intuitive procedure. I have found the learning curve is about three to five patients for surgeons unfamiliar with MIGS. The device's proximal rings are easily discerned under the gonioscopes, which helps to guide the device into position and probably accounts for the short learning curve.


My pearl is that I like to hyperinflate the anterior chamber with viscoelastic. That allows us to enter the supraciliary space from a more perpendicular approach, so we are not bumping up against the sclera. This also helps avoid creating an iridodialysis or large cyclodialysis cleft, and it helps me avoid the corneal endothelium while getting the device right into the supraciliary space. When sliding the guide wire into the supraciliary space, get as radial as possible to the globe and have the device perpendicular to the iris plane. Tap the end of the CyPass device so the proximal end is visualized between the pigmented trabecular meshwork and Schwalbe line. If you go more posterior, then these devices may become occluded with iris tissue. If you go more anterior, you are going to end up with corneal endothelial problems later on. Finally, remove the ophthalmic viscosurgical device. It is a highly straightforward procedure.

**Dr. Samuelson:** Unlike canal-based surgery where you want to target specific collector channels, one of the nice things about supraciliary surgery is that you do not have to select a specific location within the angle to implant the device, correct?

**Dr. Vold:** As long as the device is in the correct space, no matter where the placement is, it really should open the access to uveoscleral system there. But there are some things you want to avoid like blood vessels in the angle. Sometimes that means avoiding the 3 and 9 clock hour positions. That is where

# Managing your glaucoma patients with certainty.

## ZEISS Progression Analysis Tools



HD Angle Scan

### Unsurpassed ZEISS Guided Progression Analysis™ (GPA™)

- CIRRUS™ HD-OCT with GPA for RNFL and Ganglion Cell Analysis.
- Humphrey® Field Analyzer (HFA™ ZLW) with Cirrus™ HD-OCT
- Glaucoma Workplace for gold-standard structure and function analysis.

### Advanced Anterior Segment Analysis

- CIRRUS HD-OCT HD Angle Scan with measurement tools for angle closure risk assessment.

Call 1 800-342-9821 for solutions for your practice.

some of the bigger vessels are, and you may want to avoid rupturing them during surgery. When you are performing a gonioscopy, look for those angle vessels. Sometimes you will see large undulating vessels in the angle, and you want to avoid damaging them in surgery.

## InnFocus MicroShunt

**Dr. Samuelson:** What has your experience been with the InnFocus MicroShunt?

**Dr. Vold:** The InnFocus MicroShunt is a minimally invasive, standalone procedure potentially useful for a wide range of open-angle glaucomas (Figure 6). It has not been approved yet by the FDA.

The drainage implant consists of an extremely small micro-tube that shunts aqueous fluid from the anterior chamber of the eye to a subconjunctival/sub-Tenon flap. It is a bit on the longer side at 8.5 mm, but one of the advantages is the device material [Poly(styrene-block-isobutylene-block-styrene), or SIBS] is considered one of the most biostable thermoplastic elastomeric material known to man. I was initially a bit skeptical, but we have enrolled about 50 patients in the study, and every one has been a success thus far. That is pretty impressive.

The InnFocus device implantation is very similar to doing a trabeculectomy. You are making a little bit of a scleral tunnel to slide in the device. You do not use a flap. The InnFocus MicroShunt has fins on the device that allows it to stay in its proper position.

The clinical trial is ongoing, but the most recent data reported by Batlle et al<sup>12,14</sup> observed 22 eyes for 3 years after InnFocus implantation. IOP was reduced to 10.7 mm Hg in 55% of the patients, while more than 80% of patients achieved an IOP of  $\leq 14$  mm Hg. Sixty-four percent of patients did not need glaucoma medication at the third year of the study. There were no leaks, infections, migrations, erosions, persistent corneal edema, or serious long-term adverse events.

**Dr. Samuelson:** My impression is that the InnFocus device is going to be intuitive to glaucoma surgeons because it is a maneuver they make in the OR every day.

**Dr. Vold:** From my perspective, thus far, I have been extraordinarily impressed at the biocompatibility of the InnFocus device. These eyes are amazingly quiet early in the postoperative course, and patients have recovered vision rapidly following surgery. I am cautiously optimistic that both the Xen45 and Innfocus devices offer significant steps forward in traditional filtration surgery. These are exciting times for the glaucoma surgeons.

Overall, when you use any of these devices, I think there is a significant ease in the recovery process and less medications for the patient. No matter which canal-based surgery you select, it is important to use corticosteroids such as loteprednol drops

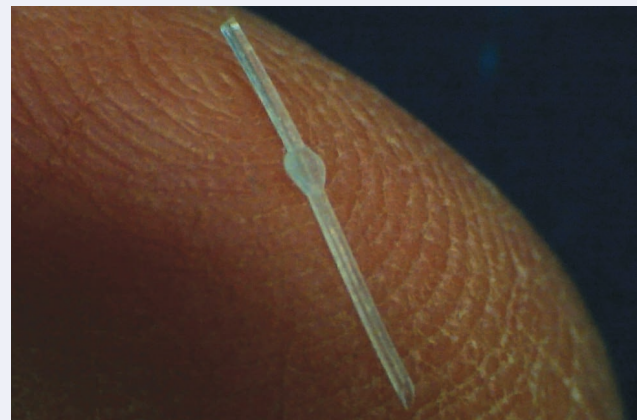

Figure 6. The InnFocus MicroShunt.

(Courtesy of InnFocus and Sarnet)

in order to avoid some of these steroid-induced IOP spikes that can occur after all angle procedures.

## New Devices Versus Standard-of-Care Procedures

**Dr. Samuelson:** Given the advancement with these devices, in what situation would you still perform a traditional trabeculectomy?

**Dr. Vold:** I am trying to avoid doing a trabeculectomy as much as possible these days. The advantage of trabeculectomy is that you can titrate it by cutting sutures or using adjustable sutures, but the complication profile is a real disadvantage, and well known. I would prefer to do Xen45 or an InnFocus implantation before a trabeculectomy in most advanced open-angle glaucoma cases. I have not had issues with flat chambers with either device, and with the InnFocus, I have yet to have to perform bleb needling, which is pretty amazing.

**Dr. Samuelson:** I needle blebs before I go back to medication. It may be a never-ending challenge to deal with subconjunctival fibrosis and scarring within that space.

I do agree that we are minimizing our manipulation so much with these newer transscleral devices that hopefully it will significantly reduce the fibrotic effect. Do you ever anticipate either of these devices replacing aqueous drainage devices?

**Dr. Vold:** There is a role for aqueous drainage devices in patients with inflammatory and neovascular glaucomas. There is a risk in causing endothelial cell damage in patients who have compromised corneas or in patients who have had a prior penetrating keratoplasty or corneal transplants. It is very important to keep these traditional tubes away from the cornea. Proper placement is critical.

There is going to be overlap in these categories. I think in patients with mild to moderate glaucoma, defined as some



early optic nerve damage but no visual field loss, there is going to be a lot of interest in the angle procedures such as iStent, Hydrus, CyPass, Kahook Dual Blade (New World Medical), or Trabectome (NeoMedix).

Kahook Dual Blade Device has been studied in multiple glaucomas, including but not limited to: primary open-angle glaucoma, pseudoexfoliation glaucoma, chronic angle closure glaucoma.<sup>15</sup> Enrolled subjects demonstrated range of severity, from mild to severe. The dual blade design makes parallel incisions to strip portions of trabecular meshwork and inner wall of canal of Schlemm.

The Trabectome is for mild to moderate primary open-angle glaucoma. It involves removal of a strip of trabecular meshwork and inner wall of Schlemm canal.

### Patient Selection

**Dr. Samuelson:** Any tips for patient and procedure selection?

**Dr. Vold:** Use gonioscopy and ensure there are not a lot of synechiae present. For example, if a patient has had some angle closure, or a lot of inflammation in the past, he or she is not the best candidate for a trabecular bypass. Trabecular bypass procedures do not work as well if the patient has used medications for an extended period or if the patient has more advanced disease.

**Dr. Samuelson:** How do you go about selecting a site to place a device? Do you look for specific clues in the angle?

**Dr. Vold:** I look for pigmentation. You can really see pigmentation in the nasal angle where a lot of the collector system channels are. I also intentionally induce a little bit of hypotony to help target the collector channels to see exactly where the blood is coming into the angle just prior to inserting a trabecular bypass device.

**Dr. Samuelson:** That is a great tip, to induce a little hypotony, and identify the blood reflux in the canal, and then target that area. You know you are in fairly close proximity to a collector.

### Conclusion

**Dr. Samuelson:** Thank you, Dr. Vold, for providing terrific insight and numerous surgical pearls. There has never been greater interest and excitement related to glaucoma

surgery, and we are grateful that you took the time to share your experience. We will be adding content to this site over the next several months and hope to provide a one-stop resource for updates within the MIGS space. ■

- Jampel HD, Friedman DS, Lubomski LH, et al. Effect of technique on intraocular pressure after combined cataract and glaucoma surgery: An evidence-based review. *Ophthalmology*. 2002;109(12):2215-2224; quiz 25, 31.
- Hayashi K, Hayashi H, Nakao F, Hayashi F. Effect of cataract surgery on intraocular pressure control in glaucoma patients. *J Cataract Refract Surg*. 2001;27(11):1779-1786.
- Glaukos. FDA approval of the iStent Trabecular Micro-Bypass. <http://investors.glaukos.com/Investors/Press-Releases/Press-Release-Details/2012/FDA-Approval-Of-The-iStent-Trabecular-MicroBypass/default.aspx>. Published June 25, 2012. Accessed April 11, 2017.
- Craven ER, Katz LJ, Wells JM, et al. Cataract surgery with trabecular micro-bypass stent implantation in patients with mild-to-moderate open-angle glaucoma and cataract: two-year follow-up. *J Cataract Refract Surg*. 2012;38(8):1339-1345.
- Katz LJ, Erb C, Carceller GA, et al. Prospective, randomized study of one, two, or three trabecular bypass stents in open-angle glaucoma subjects on topical hypotensive medication. *Clin Ophthalmol*. 2015;9:2313-2320.
- Abdullah S, Jasek MC, Radcliffe NM, et al. A novel dual blade device for goniotomy: initial clinical experience. *Invest Ophthalmol Vis Sci*. 2016;57(12):6522.
- Gong H, Francis A. Schlemm's canal and collector channels as therapeutic targets. In: Samples JR, Ahmed I, eds. *Innovations in Glaucoma Surgery*. New York: Springer; 2014:3-25.
- Cha EDK, Xu J, Gong H. Variations in active areas of aqueous humor outflow through the trabecular outflow pathway. *Invest Ophthalmol Vis Sci*. 2015;56(7):4850.
- ClinicalTrials.gov. Safety & effectiveness study of the Hydrus device for lowering IOP in glaucoma patients undergoing cataract surgery. <https://clinicaltrials.gov/ct2/show/NCT01539239>. Updated March 13, 2015. Accessed May 30, 2017.
- Pfeiffer N, Garcia-Fejoo J, Martinez-de-la-Casa JM, et al. A randomized trial of a schlemm's canal microstent with phacoemulsification for reducing intraocular pressure in open-angle glaucoma. *Ophthalmology*. 2015;122(7):1283-1293.
- Allergan. Allergan receives FDA clearance for the XEN Gel Stent, a new surgical treatment for refractory glaucoma. <https://www.allergan.com/news/news/thomson-reuters/allergan-receives-fda-clearance-for-the-xen-gel-st>. Published November 22, 2016. Accessed April 10, 2017.
- Battle JF, Fantes F, Riss I, et al. Three-year follow-up of a novel aqueous humor microShunt. *J Glaucoma*. 2016;25(2):e58-65.
- Vold S, Ahmed I, Craven ER, et al. Two-year COMPASS Trial results: supraciliary microstenting with phacoemulsification in patients with open-angle glaucoma and cataracts. *Ophthalmology*. 2016;123(10):2103-2112.
- InnFocus. InnFocus MicroShunt 3-year results of a long term clinical trial show long lasting IOP reduction. <http://innfocusinc.com/index.php/news/innfocus-microshunt-3-year-results-of-a-long-term-clinical-trial-show-long-lasting-iop-reduction>. Published January 28, 2016. Accessed April 10, 2017.
- Sarkisian SR, Allan EJ, Ding K, et al. New way for ab interno trabeculotomy: initial results. Presented at: ASCRS; April 17, 2015; San Diego, Calif.

#### Thomas W. Samuelson, MD

- adjunct professor, University of Minnesota, Minneapolis
- attending surgeon Minnesota Eye Consultants, Minneapolis
- [twsamuelson@mneye.com](mailto:twsamuelson@mneye.com)
- financial disclosure: consultant to Alcon, Allergan, Glaukos and investigator for InnFocus

#### Steven D. Vold, MD

- cataract and glaucoma surgery consultant at Vold Vision in Fayetteville, Arkansas
- chief medical editor, *Glaucoma Today*
- [svold@voldvision.com](mailto:svold@voldvision.com)
- financial disclosure: consultant to Alcon, Allergan, Ellex, Glaukos, InnFocus, Ivantis, and NeoMedix