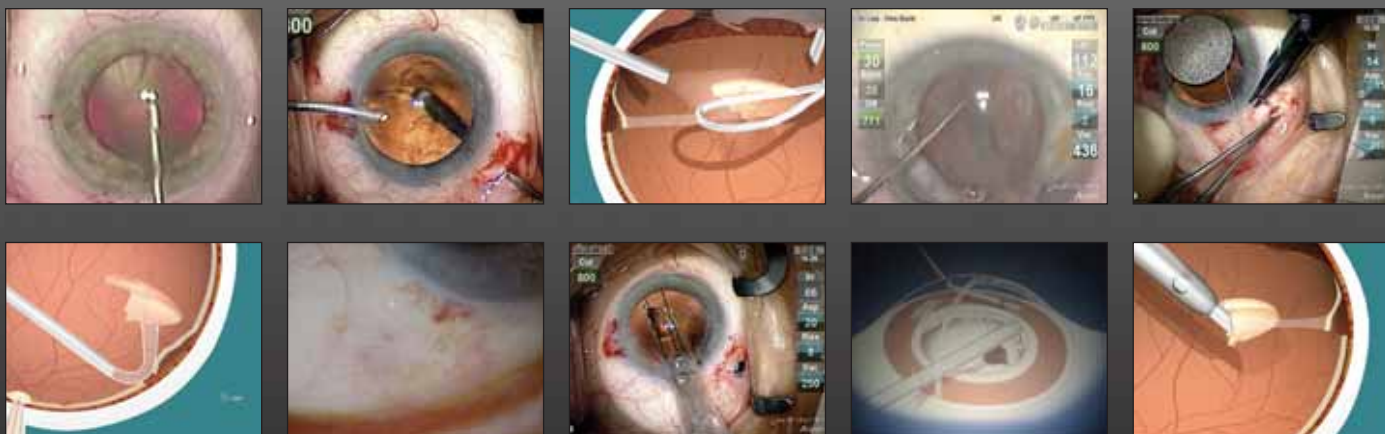


Cataract & Refractive Surgery **TODAY**

January 2012

When the Room Gets Quiet

Comprehensive strategies for unplanned vitrectomy
for the anterior segment surgeon.



A monograph and DVD based on the live surgery course
given by Lisa B. Arbisser, MD.

PLUS: A DVD OF SURGICAL VIDEOS AND A DIGITAL VERSION AVAILABLE AT EYETUBE.NET

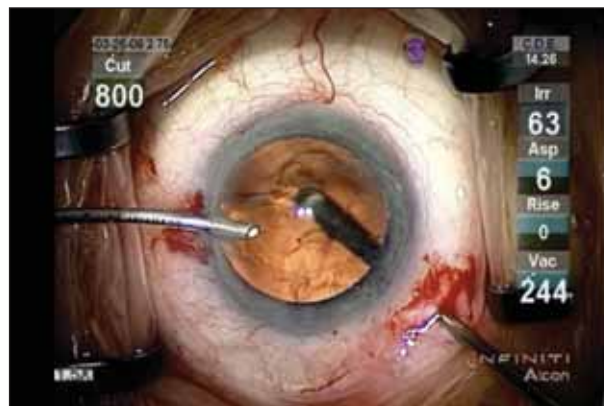
An Ounce of Prevention

All ophthalmic surgeons must have a comprehensive strategy for managing surgical complications.



Many opinions and recommendations exist for handling complicated cataract surgeries. This monograph contains mine. I was trained as a comprehensive ophthalmologist, and for many years I performed scleral buckles, trabeculectomy, and penetrating keratoplasty before concentrating on cataract surgery and anterior segment reconstruction. The strategies I have developed for managing complex and complicated cataracts over decades of practice are enhanced by close collaboration with retinal surgeons as well as laboratory exploration. I hope this information will help you to organize your thoughts and have a cogent strategy at hand for 'when the room gets quiet.'

—Lisa B. Arbisser, MD



An unplanned vitrectomy.

To view a digital version of this monograph with the videos from the accompanying DVD as well as additional materials, visit <http://www.Eyetube.net/unplanned-vitrectomy>.

Table of Contents

3	Preoperative Evaluation of Problematic Eyes	11	Rationale for a Pars Plana Incision
3	Preventing Complications	12	Vitrectomy Goals and Parameters
5	Early Stages of Complications	13	Getting Started
6	Stages of Complications	15	Suturing of Direct Sclerotomy (20- or 23-Gauge)
8	Anesthesia	15	Sutureless Vitrectomy (23- or 25-Gauge Trocar Cannula System)
8	Making the Decision to Perform Phacoemulsification or Convert to a Manual Technique	16	Residual Cortex Removal
10	Managing a Dropped Nucleus	17	Implanting an IOL
10	Particulate Marking	18	Removing OVD and Closing the Eye
11	The Anterior Incision	19	Conclusion

Comprehensive Strategies for Unplanned Vitrectomy for the Anterior Segment Surgeon

Nowhere is the adage, "An ounce of prevention is worth a pound of cure" more apt than when it comes to complication prevention during cataract surgery.

BY LISA B. ARBISSER, MD

PREOPERATIVE EVALUATION OF PROBLEMATIC EYES

- Consider peribulbar anesthesia
- Keep vitrectomy instrumentation on standby
- Book additional time for difficult/complex cases
- Have back-up implants available
- Classify cases per level of difficulty

As all cataract surgeons know, certain cases present a red flag. Any type of zonular issue is problematic. We should anticipate compromised zonular integrity after ocular trauma, with very asymmetric cataracts, in eyes with pseudoexfoliation or an asymmetric anterior chamber, and in those that have undergone pars plana vitrectomy or peripheral iridectomy. Very dense brunescence, intumescence, small pupils, and floppy irides can raise the chances of a capsular rent. We as surgeons should diligently prepare for such complications.

Although most cataract surgeons use topical anesthesia the majority of the time (I use topical and intracameral lidocaine in 95% of eyes), we can consider a peribulbar approach for patients who cannot cooperate for an indirect examination or tolerate light. Certainly, the peribulbar method works for challenging cases, such as when we know zonules are missing or when we might need to sew the iris.

It is important to keep vitrectomy instrumentation on standby and plan for additional case time for compromised eyes. I grade my cataract surgeries on levels one through four (routine to challenging), and I allow time in each surgical day for as many level ones and twos as need be. I consider level-three cases to include very small pupils, extremely brunescence lenses, and pseudoexfoliation—eyes that may be a little unpredictable. I limit these cases in the surgical schedule and place them at the end of the morning and the

end of the afternoon. A level-four case is one that I know will require tension rings, iris suturing, etc., such as subluxated crystalline lenses or implants. I reserve these surgeries for the end of the day and schedule only one per day. This allows me to pace myself and not feel pressured by waiting patients.

PREVENTING COMPLICATIONS

Recognize Zonular Laxity

Learn to recognize zonular laxity by the pin cushion effect (Figure 1). Difficulty opening the capsule or a dimple-down action with striae going out to the periphery indicate the likelihood of zonular issues. The sooner you can recognize the potential problem, the sooner you can act to prevent a complication. Always have expander hooks available.

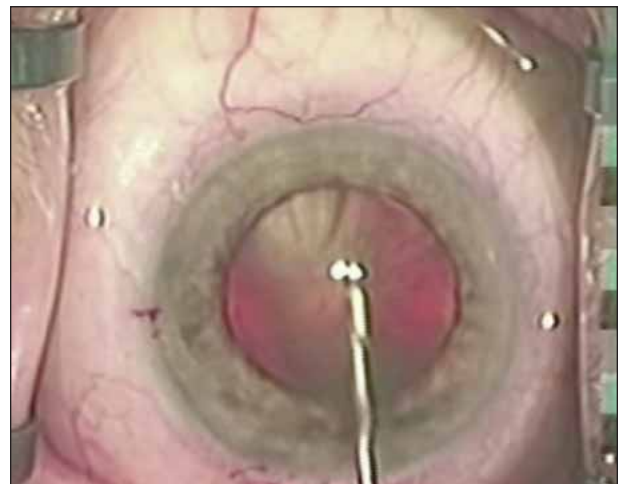


Figure 1. An eye with loose zonules shows significant striae (the dimple-down or pin cushion effect) when the author places pressure on the cornea.

Avoid Convexity of the Lens Dome

To avoid convexity of the lens dome, especially if the anterior chamber is crowded, I recommend using mannitol (0.25 gram per kilogram of IV push) 15 minutes preoperatively to deturgesc the eye and create a little more space. This tactic often avoids the need for a dry vitreous tap in shallow-chambered eyes. In eyes with shallow chambers or posterior pressure, such as pediatric cases or intumescence, use a more viscous-cohesive viscoelastic, such as Healon GV (Abbott Medical Optics Inc.) or DisCoVisc OVD (Alcon Laboratories, Inc.), or a viscoadaptive agent such as Healon5 (Abbott Medical Optics Inc.) or DisCoVisc OVD (Alcon Laboratories, Inc.). These OVDs will help prevent the capsulorhexis from running downhill.

Burp the Bag to Prevent Tamponade of the Continuous Curvilinear Capsulorhexis (CCC)

During hydrodissection, you may burp the capsular bag by rocking the nucleus slightly as the fluid wave progresses. This maneuver will prevent the edge of the capsule from adhering to the anterior cortex, which can cause the posterior capsule to blow out. Be careful not to create a vigorous fluid wave in a crowded chamber.

Mobilize the Nucleus; Beware of Fibrosis

Do not hydrodissect capsular cortical adhesions, particularly in the presence of posterior cortical adhesions (also known as *posterior polar cataracts*). Only hydrodelinate these eyes, or else you may tear the capsule in those areas. Eyes with significant peripheral cortical fibrosis require thorough hydrodissection. Watch the whitish cortical change on the surface; it will change clock hours when you rotate the lens and will not bounce back. If the nucleus bounces back when you try to turn it, it is likely that you are just stretching the zonules and have not really freed the lens from its attachments to the capsular bag. It is always best to start phacoemulsification with the nucleus free, particularly with dense lenses.

Respect the Zonules During Nuclear Rotation

When rotating the nucleus, I recommend using a two-handed technique to avoid applying downward pressure, although one instrument may be used with appropriate vector force to avoid stretching or breaking the zonules (particularly subincisional zonules).

Keep the Phaco Tip in the "Safe Zone"

The beauty of the vertical phaco chop technique for nuclear disassembly, as opposed to a divide-and-conquer or a horizontal chop, is that it keeps the instruments inside the anterior capsulorhexis. When you engage foot position three in ultrasound, it is beneficial for the phaco needle to be within the safe zone, where it remains visible. Only commence phacoemulsification once you have visualization,

AN EDUCATED STAFF IS CRITICAL

Staff members who know what to do in the event of an intraoperative complication are invaluable. If your staff members have little experience with complicated cases, I suggest conducting training sessions so they know what materials are needed. Also, I recommend assembling a "vit kit" of the tools and medications you need to handle an intraoperative complication (including backup IOL implants). Furthermore, as the surgeon, you need to know what settings on your phaco machine you will use in an emergency. From time to time, my staff and I practice a vitrectomy drill I call "code V." We pretend we have a complication, and we make sure everybody knows what needs to be done, similar to practicing CPR.

because you will be much less likely to engage the peripheral capsule.

Know Where the CCC's Edge Is and Protect the Vector

When making the capsulorhexis, know where its edge is at all times. You can control the vector of the tear by regrasping the edge of it. If the vector is appropriate and the patient moves, the capsulorhexis will not tear out to the periphery but simply come into the center and end early. Try not to blink while making the capsulorhexis, because if the vector shifts in an unpredictable direction from the tear, you want to catch it within 0.50 to 1.00 mm. If the capsulorhexis tears out to the equator, it will be difficult to recover.

If viewing the edge of the capsulorhexis is challenging, stain it with trypan blue dye. You can "paint" the stain on to reveal the details of the capsule at any stage. Also, pay attention to the edge of the capsulorhexis while disassembling the nucleus, especially if you are using a horizontal chopper that you must take out beyond the equator and underneath the edge of the capsulorhexis.

Keep the Main Incision and Paracentesis Small to Control Fluidics

All surgeons are mindful of the size of their main incision, but for some reason, we are taught to make a 1-mm paracentesis. Richard Mackool, MD, once measured a loss of 22 mL/min of balanced salt solution out of a 1-mm paracentesis (Richard Mackool, MD, e-mail communication, April 14, 2011). I use a small-profile Rosen phaco splitter (Katena Eye Instruments, Inc.) as my chopper to keep the paracentesis smaller than 0.5 mm. This reduces the amount of flow and turbulence in the eye and prevents me from having to chase particles over to the incision.

Understand Your Phaco Machine's Settings and Dynamics

Phacoemulsification requires hand/eye/foot/ear coordination. It is critical to understand the settings on your

phaco machine and not just “set it and forget it.” If you are inexperienced, practice with the foot pedal without a patient. Listen to the sound of the pump when you pinch the tubing to create occlusion. Become adept at staying in foot position 1 and easily moving from position 3 to 2 without losing vacuum. If a case starts to go awry, you need to know how to manage it. Should you reduce the flow rate? Do you need to increase or decrease the vacuum or raise the irrigation bottle? Is chatter an issue that requires a decrease in phaco power? Be alert to occlusion tones, and know what the machine’s rise time is and how it will facilitate a case.

Use the Chopper to Shield the Posterior Capsule During Final Fragment Removal

It is prudent to hold the nondominant-hand instrument behind the phaco tip during phacoemulsification to shield the posterior capsule. Sharp-tipped choppers should not be used and are not needed, even for vertical chop in densely brunescient lenses. Surge at the phaco tip can snag the posterior capsule, particularly when emulsifying dense or final remaining fragments. Consider stepping down the fluidics for removing final fragments if your usual settings are aggressive.

Maintain the Capsular Cul de Sac During I/A

It is helpful to use a silicone instead of a metal I/A sleeve. A silicone sleeve will fill and conform to the incision to promote a closed chamber while performing I/A, which helps expand the cul de sac, provides better access to the cortex, and reduces the chance of accidentally grabbing the capsule. Consider polishing rather than vacuuming the posterior capsule, especially when zonular behavior is abnormal.

Keep the Posterior Capsule Concave for IOL Insertion

Make sure there is enough viscoelastic in the eye to keep the capsule concave when you insert the IOL. You do not want to displace the subincisional zonules by snagging the capsule with the leading edge of the implant.

Maintain Positive Pressure During Patient Valsalva

Maintaining a positive pressure during patient valsalva is very important. Many surgeons will rapidly remove their instruments from the eye if a patient starts to cough, which allows the chamber to collapse, can cause incisional prolapse of the iris, and invites retrodirected fluid later in the case. We must instead maintain positive pressure. Lock your hands onto the patient’s face, and train the scrub nurse to lay a hand on the patient’s forehead to hold the head on the table. Stay in foot position 1 or 0 (never 2 or 3), and keep a positive pressure. This will maintain physiologic relationships within the eye and prevent complications associated with valsalva.

Maintain a Normotensive Eye and Normal Physiologic Tissue Relationships Where Possible

The eye is most vulnerable when we remove instruments from it through an incision that is not truly closed, which leaves low pressure in the chamber. I support the anterior chamber with balanced salt solution (BSS; Alcon Laboratories, Inc.) that I irrigate through the sideport incision before I remove the phaco and I/A tips. In susceptible cases such as high myopes and vitrectomized eyes, avoid iris retropulsion via overfilling the chamber by lifting the iris off the anterior capsule with your nondominant-hand instrument while initiating foot position 1.

EARLY STAGES OF COMPLICATIONS

Recognition

- Sudden pupillary bounce or change in pupil size
- Change in anterior chamber depth during phacoemulsification or I/A
- Inappropriate loss of followability of lens material
- Unexplained loss of phaco efficiency
- Tilt of nucleus equator
- Spidering of the posterior capsule or an unusually clear spot
- Wound will not seal despite proper construction
- Peaked pupil

A rupture in the posterior capsule and, in particular, the anterior hyaloid will change the pressure relationship between the anterior and posterior chambers and the posterior segment. This change in IOP will in turn affect the anterior chamber’s depth and, often, the pupil’s size, and the pupil may suddenly bounce (Figure 2). An increase or decrease in the anterior chamber’s depth during phacoemulsification or I/A are both warning signs, unless there is a good explanation for the change. You must determine what occurred.

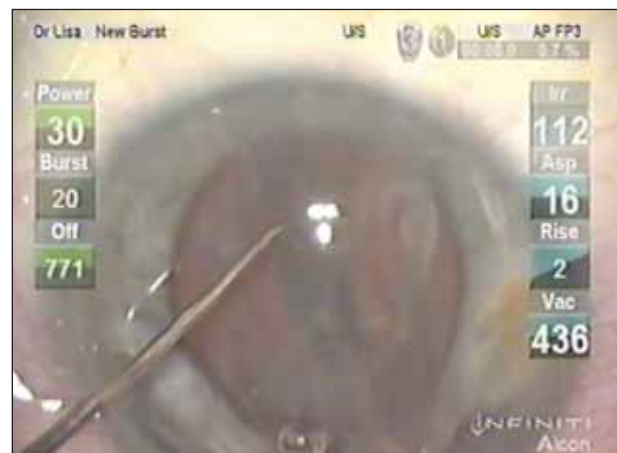

Figure 2. In pupillary bounce, the pupil rises up to fill the anterior chamber.

Because vitreous follows a gradient from high to low pressure, it will always preferentially seek the flow into the phaco tip and obstruct the tip. If lenticular material suddenly stops coming to the phaco tip, there is likely vitreous in the way.

The classic signs of vitreous loss are an asymmetrically enlarged pupil and remote movement of the iris when you touch the incision. Another ominous sign of vitreous loss is tilting of the nucleus' equator or loss of mobility in a previously rotatable nucleus. Seeing clear space beyond the equator or having the equator come into view after removing the nucleus are sure signs of zonular loss. A subtle sign of the presence of a strand of vitreous may be the inability to seal a properly constructed incision.

Response

- **Do not withdraw the phaco instrument**
- **Go to foot position 1 (stop phaco and aspiration)**
- **Maintain chamber stability; don't allow a collapse**
- **Fill the chamber with enough dispersive viscoelastic through the sideport to close the incision as you withdraw the phaco tip**
- **Assess the situation: Inspect, relax, think, and announce a delay**

Once you realize you have lost vitreous, it is natural to want to withdraw your hand immediately, but this will lower the IOP in the anterior chamber and invite vitreous to come forward, thereby increasing the tear in the capsule and causing vitreous to follow the instrument out of the incision. The moment you suspect an issue, you must cease phacoemulsification and aspiration and stabilize the anterior chamber. Go to foot position 1 or 0 (depending on how watertight the incision is), ask the nurse to exchange your chopping instrument with viscoelastic (preferably a dispersive agent like VISCOAT OVD [Alcon

Laboratories, Inc.]), and fill the anterior chamber with OVD through the sideport incision. Only then should you withdraw your phaco instrument, assess the situation, relax, think, and announce the delay. Because I often have a patient in the other room about to be draped, I will say "timing" to my staff when a complication occurs, and everyone knows to suspend preparations for that patient while we manage the issue in the OR.

STAGES OF COMPLICATION

- **Broken posterior capsule with intact hyaloid**
- **Vitreous prolapsed into the anterior segment**
- **Vitreous loss through the incision**
- **Retained lens material**

The prolapse and loss of vitreous does not always have to happen. If we can recognize a broken posterior capsule with an intact hyaloid, then we can take steps to curtail the level of damage at that point. Ideally, we want to create a true posterior capsulorhexis in order to maintain the integrity of a broken capsule and of the intact hyaloid face.

The next stage of complication is vitreous prolapse into the anterior chamber. *Loss of vitreous* means that the vitreous has already progressed out through the incision (see *Lessening the Rate of Vitreous Loss*). Each step, of course, changes the amount of intraoperative vitreous traction on the vitreous base. The farther the vitreous travels, the more likely a retinal tear or detachment becomes. Retained lens material can complicate the situation at any stage.

Unifying Principles

- **Prevent intraoperative vitreous traction**
- **Avoid postoperative vitreous traction**
- **Maintain a normotensive globe**

LESSENING THE RATE OF VITREOUS LOSS

The incidence of vitreous loss reported in the literature is between 0.45% and 14%.^{1,2} Recently, the *Journal of Cataract & Refractive Surgery* published the results of a study of more than 600,000 cataract surgeries as recorded in the Swedish National Cataract Registry from 2002 to 2009 in which the incidence of capsular complications was 2.09%.³ Based on the ratio of sales of phaco packs to vitrector packs, the U.S. ophthalmic industry estimates that vitreous loss occurs at a rate of 2% to 5%. Of course, vitreous loss often goes unreported or is managed without opening a vitrectomy probe. I think that with today's phaco technology, experienced surgeons should be able to keep the incidence of vitreous loss well under 1%. I feel that each cataract surgeon should examine his or her rate of vitreous loss. If it is above 2%, I submit that remediation is deserved. Although vitreous loss cannot be entirely avoided, the better we can identify potential problems before they happen, the better we will be at handling a complication. My goal is to try to never lose vitreous the same way twice. I believe it is valuable to run a video camera during all cases so we can understand what went wrong when a complication occurs and hopefully prevent it in the future.

1. Gimbel HV. Posterior capsule tears using phacoemulsification causes, prevention and management. *Eur J Implant Refract Surg.* 1990;2:63-69.

2. Allinson RW, Metrikin DC, Fante RG. Incidence of vitreous loss among third year residents performing phacoemulsification. *Ophthalmology.* 1992;99:726-730.

3. Lundstrom M, Behndig A, Kugelberg M, et al. Decreasing rate of capsule complications in cataract surgery: Eight-year study of incidence, risk factors, and data validity by the Swedish National Cataract Register. *J Cataract Refract Surg.* 2011;37(10):1762-1767.

- **Protect tissues (cornea, iris, capsule) from collateral damage**
- **Leave a clean anterior segment**

There are unifying principles to all surgery, but particularly in complicated intraocular cases involving vitrectomy. Primarily, we want to prevent vitreous traction intraoperatively and avoid it postoperatively (*see Is Vitrectomy Always Necessary?*). Poor visual results do not occur from losing vitreous, but from the complications associated with the sequelae of a retinal tear and detachment, which all relate to intraoperative as well as postoperative vitreous traction. The goal is to maintain a normotensive globe throughout the procedure as much as possible, because a highly hypotensive globe invites the potential for such complications as suprachoroidal hemorrhage, cystoid macular edema (CME), and the ingress of fluid and bacteria and therefore endophthalmitis. Furthermore, high IOP in the globe is obviously not a good idea for circulation, certainly not for prolonged periods of time.

When we break a capsule or lose vitreous, protecting the tissues (cornea, iris, capsule, macula) from collateral damage is an additional concern. We do not want to ruin the endothelium and necessitate a corneal transplant, chew up the iris, or sacrifice any capsule (which is critical to a stable lens implantation) just because we broke a capsule or lost vitreous. If the complication will lengthen the surgery, we want to shield the macula from the microscope's light whenever possible. I believe our goal as anterior segment surgeons is to leave a clean anterior segment—a stable lens, no retained cortex, as intact a capsule as possible, and a healthy cornea and iris—for the best outcome.

Controlling the Damage

- **Use a dispersive and cohesive viscoelastic to compartmentalize and pressurize the eye**
- **Convert a posterior-chamber rent to a CCC if possible**
- **Raise remaining nuclear fragments above the iris:**
 - Pupillary stretch or microsphincterotomies
 - CCC's enlargement preferred over relaxation incisions; avoid can-opener cuts
 - Dial, lift, cantilever, and float with viscoelastic

Once vitreous begins to prolapse, use a dispersive viscoelastic to separate the lens material from the vitreous as much as possible so they do not become entangled. True compartmentalization means first using a dispersive viscoelastic (such as VISCOAT OVD) over the area you want to isolate, such as a tear, and then barricading the dispersive agent by adding a cohesive viscoelastic such as PROVISC OVD (Alcon Laboratories, Inc.) behind it. As the cohesive agent dissipates, you can work where that agent used to be while the remaining dispersive OVD keeps the eye compartmentalized. The goal is to convert any posterior capsular break or rent into a true posterior

IS VITRECTOMY ALWAYS NECESSARY?

Must we always remove prolapsed vitreous with a vitrector? Because the goal is to prevent intra- and postoperative vitreous traction, we cannot leave a connection of prolapsed vitreous forward where it can attach to anterior structures or find its way out of a leaky incision. It may be possible to avoid automated vitreous removal if there is a small strand or a small amount of vitreous that can be cut from its anterior connection with intraocular scissors and forced back to the posterior segment with OVD. We cannot, however, perform vitrectomy with a Weck-Cel (cellulose) sponge (Medtronic ENT), because it will generate force on the vitreous base. We must make sure there is no vitreous left at the conclusion of manual vitrectomy. If this simple maneuver doesn't do the job, we must decide on the best automated approach for the case.

CCC. Even when the rent appears round, minimal force can cause it to extend, because only a true CCC that finishes outside of where it began has full strength. When you recognize a break in the posterior capsule, first stabilize the anterior chamber with dispersive OVD, then gently irrigate a cohesive OVD into Berger's space through the tear to push back and stabilize the hyaloid. At this point, grasp the edge of the posterior capsule with capsulorhexis forceps (you may need to first create an edge with scissors; *see Vitrectomy Instrumentation*). The vector must be fairly centripetal to facilitate the continuous tear and keep the opening as small as possible. It is not possible to do this maneuver efficiently in the presence of prolapsed vitreous through the tear.

If any nuclear fragments remain in the posterior chamber (not in the posterior segment below the posterior capsule), raise them up above the iris in order to separate them from vitreous for extraction. If the pupil is small and additional intracameral bisulfite and preservative-free epinephrine does not enlarge it adequately, performing a two-point Fry stretch pupilloplasty or microsphincterotomies can be helpful. I would not use a device such as a Malyugin ring (MicroSurgical Technology) in this setting, because I feel that introducing another device in the eye would complicate the situation and increase the risk of tearing the capsulorhexis. If needed, use iris hooks to improve your view, and be mindful of where the edge of the capsulorhexis is (perhaps even paint a little stain there if necessary) so you do not impair its edge, which is a particularly unfortunate complication when the posterior capsule is already broken.

If a small anterior capsulorhexis is holding the nuclear fragments back from the anterior chamber, I do not recommend making radial relaxing cuts or can-opener incisions in the capsulorhexis. If neither the capsulorhexis nor

the posterior capsule are intact, options for stabilizing the IOL are limited. Instead, enlarge the capsulorhexis with a tangential cut, and spiral the flap around so that it is slightly smaller in diameter than the optic of the lens you plan to implant so you can perform an optic capture. Then dial, lift, cantilever, float with viscoelastic, or somehow gently raise the lens particle up above the iris plane.

ANESTHESIA

- **Vitreous does not hurt**
- **Topical/additional drops, pledget, or sponge ring**
- **Subconjunctival lidocaine with epinephrine over the site of the pars plana incision**
- **Intracameral: expect amaurosis; won't help and not recommended**
- **Minimize IV sedation to prevent confusion and agitation**
- **'Vocal local' is the most important modality**
- **Akinesia only as needed by parabolbar or sub-Tenons irrigation**

Because it does not hurt the patient to remove the vitreous, you can treat a vitreal complication without additional anesthesia, although it may take longer and necessitate supplemental topical anesthesia. A drop of tetracaine, a pledgett, or a ring sponge soaked in the anesthetic will suffice. Be advised, however, that incising a pars plana sclerotomy will hurt the patient under topical anesthesia, so these incisions require a bleb of subconjunctival lidocaine, preferably with epinephrine, so you do not have to apply cautery. Wait 3 to 4 minutes to ensure the sclera is numb in that area prior to proceeding with a peritomy or sclerotomy.

I do not think it is appropriate to use intracameral lidocaine in the setting of broken zonules or an open capsule. Years ago, Harvey Linkoff, MD, showed that lidocaine is not toxic to the neuroretina, but it will anesthetize it.¹ The patient will experience immediate amaurosis that may scare him and you. Once the posterior chamber is open, you cannot possibly instill enough lidocaine to make a difference. Furthermore, use IV sedation with great caution—oversedating the patient is the worst thing you can do. Patients who are sedated awoken from it suddenly and often are very agitated and difficult to control. If the patient is uncomfortable, tiny aliquots of short-acting narcotics such as Alfenta (alfentanil hydrochloride injection; Akorn, Inc.) or Versed (midazolam; Hoffmann-La Roche Inc.) can be helpful. The gold standard for keeping patients comfortable during a complication is vocal anesthesia—you must sound in control and keep everyone in the room calm. Do not shout at your staff for things. If the patient is displaying wild eye movements or is becoming agitated and needs akinesia, then use a peribulbar or subtenon

VITRECTOMY INSTRUMENTATION

- calipers
- MVR blades or trocar cannula system
- angled infusion cannula or chamber maintainer
- vitreous cutter
- +/- triamcinalone acetonide
- Kansas forceps
- cautery
- vannas or intraocular scissors
- nonirrigating vectis

These various vitrectomy instruments are appropriate to have on hand in the event of vitreous prolapse. It is not an exhaustive list. We want to have scissors and a nonirrigating vectis to be able to convert to an extracapsular technique if necessary. Triescence (Alcon Laboratories, Inc.) aids in vitreous identification. You may choose to use MVR blades and/or trocars, depending on your approach. A Kansas forceps is a forceps with a lot of crosshatching in the jaws that can grab a piece of nucleus without cheesewiring through it. Cautery may be necessary at times, although I dissuade people from using it, because I think the sclera is poorly vascularized as it is, and we risk ischemia with aggressive cautery.

technique, which do not involve a sharp retro- or peribulbar injection. Of course, a retrolubar hemorrhage with an open eye would be catastrophic.

MAKING THE DECISION TO PERFORM PHACOEMULSIFICATION OR CONVERT TO A MANUAL TECHNIQUE

- **Perform phacoemulsification only if:**
 - **there is no mixture of vitreous and lens material**
 - **there is adequate compartmentalization**
 - **the rent is limited and controlled or can be covered with a lens glide**
 - **Consider miocol E to use the iris as a safety net**
 - **Optic-capture the IOL, then phaco as described by Michael Snyder, MD**
- **Note: ultrasound will not cut vitreous and will risk a retinal tear**

Once you identify either a broken capsule or vitreous prolapse, you need to decide whether you will be able to remove any remaining nucleus with phacoemulsification or if you need to convert the procedure to a manual technique. Remembering that our main tenet is to prevent intraoperative vitreous traction, the question is whether or not the lens material has mixed with vitreous, because we cannot emulsify vitreous without creating monstrous traction. The vitreous is made of fibrous strands that will not lyse. If you were to incarcerate vitreous in the phaco

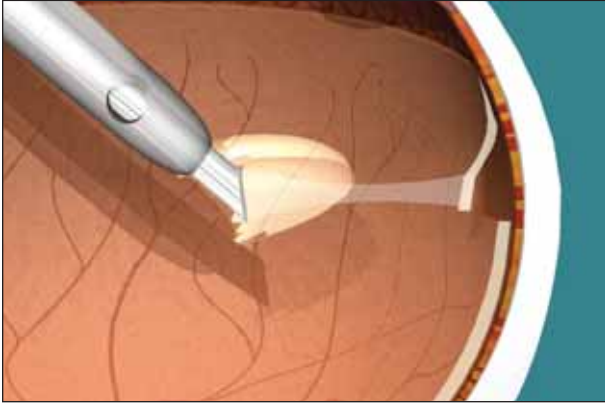


Figure 3. To avoid tearing the retina, do not allow the phaco tip to go behind the posterior capsule. (Figures 3-5 reprinted from Charles S, Calzada J, Wood B. *Vitreous Microsurgery*. 5th ed. Baltimore, MD: Lippincott, Williams, & Wilkins; 2011, with permission from Lippincott, Williams, & Wilkins.)

tip, it would place tremendous traction on the vitreous base and on the peripheral retina, which is the thinnest region. If you can be certain that you have compartmentalized the vitreous and tamponaded the rent in the capsule while successfully bringing the nuclear fragments forward, then you may consider proceeding with phacoemulsification. Although some surgeons have advocated using a lens glide, if it fits through the small incision, it usually will not cover the rent and may find its way to the iris root and cause bleeding while your attention is elsewhere. Instead, I would instill Miochol-E (acetylcholine; Bausch + Lomb) to bring the pupil down so you can deal with the fragment over the iris rather than the capsular rent. Later, use epinephrine to bring the pupil back up as needed.

A trickier option is to prematurely implant the IOL in the sulcus and perform an optic capture through the intact anterior capsulorhexis, thereby hermetically sealing the posterior segment and the posterior chamber from the anterior chamber. Then, you can remove the nucleus from above without any risk of losing it to the back of the eye. This technique can be problematic, however, if there is a lot of cortex present, or if you do not know the location of the vitreous, or if there is an uncontrolled tear in the capsule. Then, the lens may complicate the situation or may even be lost posteriorly, so you must use your judgment about how best to proceed.

Phaco Technique

- **Slow-motion phaco parameters:**
 - Low flow (25 cc/min)
 - Moderate vacuum (250 mm Hg)
 - Short bursts of low phaco energy to promote followability
 - Adequate flow to avoid burn

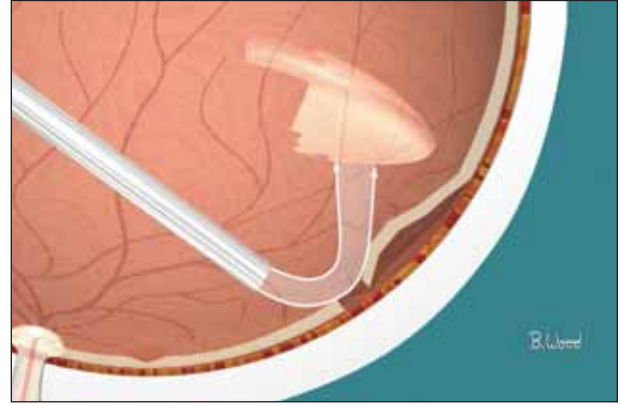


Figure 4. Irrigating into the vitreous to cause lens fragments to float out risks a retinal tear. This was a method for creating retinal detachment for research in animal models.

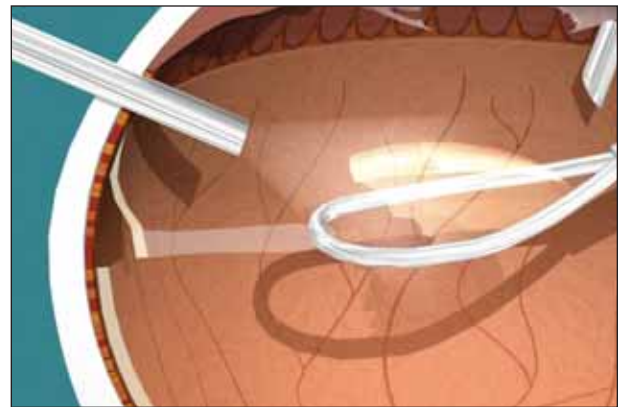


Figure 5. A lens loop placed behind the posterior capsule to retrieve a lens fragment risks a retinal tear.

Use an Osher-type slow-motion phaco technique.² Ideally, keep the flow in the range of 25 cc/min, moderate vacuum in the range of 250 mm Hg, and short bursts of low phaco energy to promote followability. The goal is to maintain adequate flow to avoid a burn (because you will be operating in a viscoelastic-filled environment) but not to propel nuclear fragments away from the phaco tip.

Conversion to Extracapsular Cataract Extraction

If you are unsure of where the vitreous is and a significant amount of nucleus is left behind, you must size your incision based on the size of the remaining fragments. I prefer a clear corneal incision no larger than 4-mm because, being avascular, it would take a long time to heal, and large incisions induce astigmatism. Regard the clear corneal incision as a superparacentesis; simply close it (making sure it is watertight), and then make the appropriately sized, standard limbal or scleral tunnel incision. You may break up the nucleus intracamerally with Kansas forceps to remove them through the smaller incision if it is feasible to do so.

If you choose to convert to an extracapsular cataract technique, do not express the nucleus with external pressure. If the capsule is not intact, then attempting to push the nucleus out by pressing on the globe's exterior and on the posterior lip of the incision will only express more vitreous and enlarge the break in the capsulorhexis. Instead, remove the nucleus with a pick, a Kansas forceps, or a vectis without using irrigation so as not to displace the vitreous with fluid. You want to glide the nucleus out in a viscoelastic sandwich without further damaging the endothelium.

MANAGING A DROPPED NUCLEUS

- **Not recommended:**
 - Phaco tip, vectis, forceps, and PAL technique
 - Chasing, irrigating posterior-segment fragments
- **Controversial: Posterior viscolevitation**
- **Most reliable outcome: Refer to a retinal surgeon for three-port vitrectomy with a fragmenter**

If I encounter a nucleus that descends below the posterior capsule, I let it go. All ophthalmic surgeons agree that the phaco tip does not belong behind the posterior capsule because of the risk of tearing the retina (Figures 3-5). The legendary Charles Kelman, MD, proposed the original posterior-assisted levitation (PAL) technique that involved inserting a spatula through the pars plana and then levitating or tire-ironing the dropped nuclear fragment into the anterior chamber. Certainly, this maneuver is capable of saving a descended nucleus, but sweeping through the vitreous is dangerous. The modification of viscolevitation—inserting a cannula of VISCOAT OVD through a pars plana sclerotomy and slowly injecting the OVD to lift the nuclear fragment anterior to the posterior capsule—is controversial. Retina specialists agree that a three-port vitrectomy using an appropriate fragmenter as needed has produced the most consistently good outcomes.

I personally do not perform viscolevitation. Preoperative cataract counseling should include a discussion about the rare chance of needing more than one surgery to remove the cataract for best results. Nuclear fragments can dislocate peripherally as well as posteriorly out of view behind the iris during viscolevitation. The pressure of injecting the OVD through the pars plana may promote more vitreous prolapse, and forces at the vitreous base can be significant and lead to a retinal tear or detachment. For a description of our experience with cadaver eyes with this technique, see the extensive article colleagues and I published in *Ophthalmology Clinics of North America*.³

PARTICULATE MARKING

- **Triamcinolone acetonide binds to vitreous**
- **Facilitates vitreous recognition and removal**
- **Reduces postoperative inflammation**
- **Washed Kenalog (off-label use)**
- **Triesence: supplied unpreserved (Alcon Laboratories, Inc.)**
- **Dilute 10:1 with BSS for particulate identification**

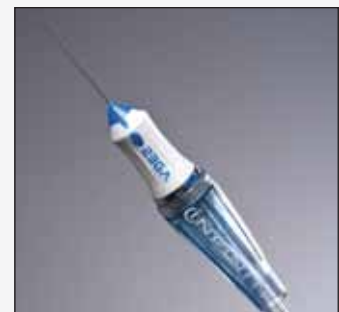Particulate staining was originally devised by Gholam Peyman, MD,⁴ of Tucson, Arizona, and then popularized in the anterior segment by Scott Burke, MD, from Cincinnati. Although Drs. Peyman and Burke originally used triamcinolone acetonide or washed Kenalog (an off-label use), we now have available nonpreserved Triesence (triamcinolone acetonide injectable suspension; Alcon Laboratories, Inc.), an on-label, preservative-free preparation used to identify the vitreous. This technique can be hugely beneficial when you suspect a hyaloid break. Like throwing a sheet over a ghost, it allows you to see the invisible vitreous beautifully (Figure 6). You must add the Triesence at the right time, when the OVD is not in the way, so that the former can bind to the surface of the vitreous. Also, the drug has the

THE ALCON ULTRAVIT VITRECTOMY PROBE

The INFINITI Vision System (Alcon Laboratories, Inc.), which I currently use in both of my ORs, has an anterior segment vitrectomy kit that serves the surgeon and staff during complications. The setup includes the new UltraVit 23 disposable vitrectomy probes that are designed specifically for the anterior segment. These probes are tapered and sized to fit 1-mm sideport incisions with minimal trauma (thus enabling a closed system). This size of probe also allows surgeons to perform sutureless biaxial vitrectomy if they prefer.

A unique pneumatic dual-drive guillotine cutter allows the UltraVit 23 probe to produce 2,500 cuts per minute. Standard vitrectomy probes have single-pressure drive actuation and therefore a much lower cutting rate (a maximum of approximately 800 cuts per minute). A higher cutting rate reduces traction on the vitreous base and thereby makes vitrectomy safer.

The UltraVit 23 probe is available on INFINITI Vision Systems that were shipped prior to September 1, 2009, as a software and hardware upgrade. The UltraVit 23 kit does not require additional training for OR staff; its use is intuitive for anyone who has a basic understanding of the principles of anterior vitrectomy.



The UltraVit 23 disposable vitrectomy probe.

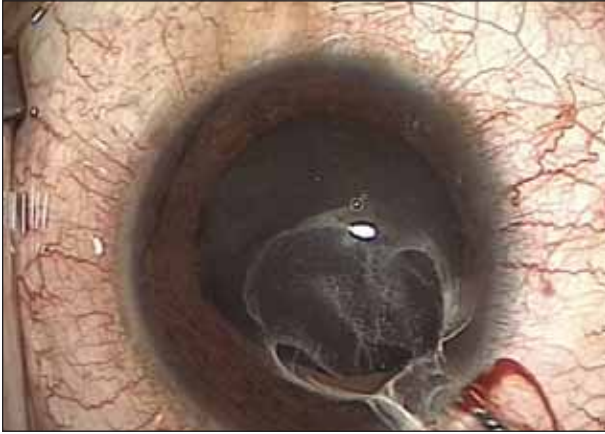


Figure 6. Particulate staining of vitreous with triamcinolone.

therapeutic effect of reducing postoperative inflammation. The preservatives in kenalog are toxic to the endothelium. Triescence has essentially replaced Kenalog, because it is FDA-approved for this purpose and is also billable.

THE ANTERIOR INCISION

- **Biaxial (separate sleeve from the vitrector shaft)**
- **Never use the primary coaxial incision site**
- **Make a new paracentesis to fit the bare vitrector shaft using the original sideport for irrigation**
- **Advance toward the vitreous while cutting**
- **Hold the eye steady; tilt the vitrector below the posterior capsule**
- **Anticipate a repeat presentation of vitreous**

Although anterior vitrectomy can be performed through an anterior or a pars plana approach, there are some absolute criteria we must follow. Whichever incision we choose, the instruments should be biaxial, with the irrigation separated from the vitrector. Although vitrectomy packs traditionally came in a coaxial configuration, interestingly, Dr. Charles has said that he never intended the Charles Sleeve for the purpose of unplanned vitrectomy, but designed it for pediatric work. We must remember that vitreous always follows a gradient from high to low pressure. If we want it to flow into the vitrector, irrigating at the tip will be counterproductive. The fluid tends to displace the vitreous body, necessitating more to be removed. The goal is to preserve as much of the vitreous structure as possible while removing any strands that have prolapsed into the anterior segment.

Irrigating through the sideport incision is ideal for encouraging vitreous to remain posteriorly and keeping higher pressure in the front of the eye. Although pars plana irrigation is optimal for our retinal surgeon colleagues, I do not recommend it in the cataract setting, because it requires posterior focusing lenses or indentation to ensure complete penetration of the choroid. Furthermore, do not insert a

bare vitrector through the main clear corneal incision, because it will not fill the wound and will allow vitreous to flow out around it. Make a new incision that is just the right size for the bare vitrector. A standard keratome will be too large; use an MVR blade or your choice of instrument to create the paracentesis. Make this incision just the right size to maintain a closed chamber.

Regardless of which incision you choose, do not move the vitrector through the vitreous without cutting. Stay in foot position 2, because vitreous can flow into the port while in foot position 1 and create traction. If you are using an anterior approach, tilt the vitrector down below the posterior capsule in order to pull vitreous back to the posterior segment. Removing or amputating anterior/posterior connections of any prolapsed vitreous can be difficult from this approach if there is a flat sheet or strand to the incision that is adherent to the iris.

Also, there is a tendency to call more vitreous forward while trying to remove the vitreous that is already forward. Once we reach an endpoint with the maneuver, the pressure is lowest in the anterior segment, which encourages vitreous to present again on subsequent maneuvers. Figure 7 shows the biaxial paracentesis incisions for the vitrector. For all these reasons, a corneal incision may not be the optimal choice, but it is mandatory when there is no view available through the pupil.

RATIONALE FOR A PARS PLANA INCISION

- **Vitreous follows a gradient from high to low pressure; leaves lowest pressure posteriorly**
- **Minimizes traction with proximity to vitreous base**
- **Most efficient, as it calls vitreous home**
- **Allows subsequent maneuvers with less re-presentation of vitreous**
- **Will not unzip zonules**
- **Facilitates amputation of vitreous within incisions without sweeping**

If you have not been trained to make a pars plana incision, go to a skills transfer lab or ask the retinal surgeon in

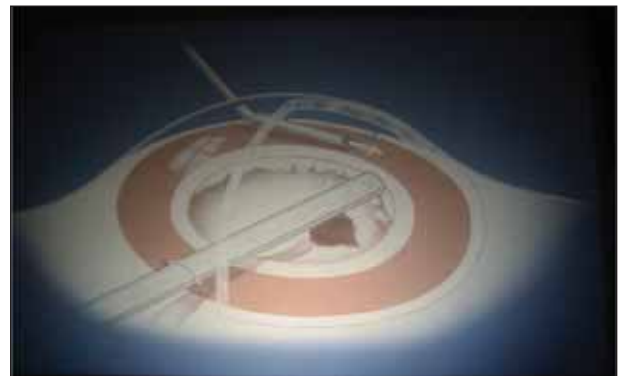

Figure 7. The biaxial paracentesis incisions for the vitrector.

your area if you can sit in and learn how to do it properly. Practice this incision ahead of time with eye bank or animal eyes, not in the heat of battle.

Again, the rationale for using the pars plana for vitrectomy is that, because vitreous follows a pressure gradient from high to low, we want to leave the lowest pressure posteriorly. We also want to minimize traction by removing the vitreous closer to its base. If any vitreous follows the instrument to the incision, it will be right near the vitreous base at the pars plana, rather than up at the corneal incision. This technique is the most efficient, because it calls the vitreous home. The pars plana technique also allows subsequent maneuvers while minimizing re-presentation of the vitreous. It will not unzip the zonules when vitreous presents around the lens equator by calling more vitreous forward through the defect. Finally, the pars plana approach facilitates amputation of the vitreous within incisions. Although we were taught to use a sweep from the sideport incision to drag entrapped vitreous away, this actually creates more traction on the connection through the pupil rather than efficiently freeing the vitreous from incarceration in the wound. I strongly discourage this practice.

VITRECTOMY GOALS AND PARAMETERS

- **Particulate identify rather than "Weck" the incision to test for vitreous loss**
- **Do not sweep the incision (traction), but rather amputate posterior attachments**
- **Confirm vitrectomy mode: irrigate, then cutting, then aspiration in foot positions 1, 2, and 3**
- **Maximize the cut rate to minimize traction**
- **Minimize the flow rate (peristaltic pump machine) to**

slow the action

- **Balance the lowest effective vacuum with the lowest bottle height to maintain normotension**
- **Remove all vitreous from the anterior chamber to below the capsular plane**
- **Minimally disrupt the posterior-segment vitreous structure**

Vitrectomy Mode: I/Cut/A

The best machine parameters for performing vitrectomy are those settings that most effectively reduce vitreoretinal traction and prevent followability. In foot position 1, you will only be irrigating. In foot position 2, you will be irrigating and cutting. Not until foot position 3 will you be irrigating, cutting, and sucking, because you do not want to apply any vacuum to the vitreous unless you are cutting it at the same time. You must always follow the sequence of irrigation, cutting, then aspiration when removing vitreous, so be certain not to use the "I/A Cut" setting, where foot position 1 is irrigation, foot position 2 is sucking, and foot position 3 is cutting. This setting will prove useful when followability is desired during removal of the residual cortex, once vitreous is likely out of the way.

Cutting Rate and Flow

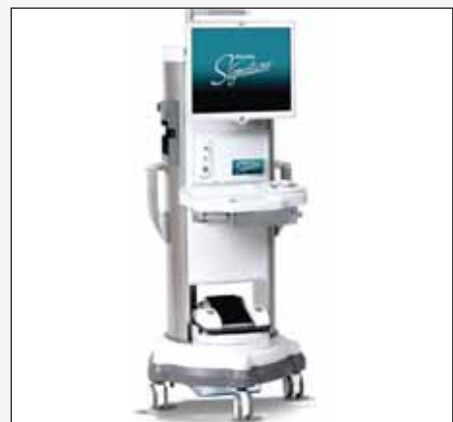Dr. Charles has coined the term *port-based flow limiting*, which describes the goal of achieving the highest cut rate possible, the lowest effective flow rate, and the lowest vacuum that generates the removal of vitreous. As the vitreous is engaged, the faster you cut, the more you reduce traction. The highest cut rate possible on some older phaco machines is 400 cuts per minute, but newer models can go

THE WHITESTAR SIGNATURE VITRECTOMY SYSTEM

The WhiteStar Signature System (Abbott Medical Optics Inc.) has advanced capabilities for anterior vitrectomy. The surgeon has a choice of two high-speed guillotine vitrectomy handpieces, the 20-gauge and the 23-gauge vitrector, the latter of which can be paired with a separate irrigator for bimanual clear cornea or pars plana vitrectomy through sutureless incisions as small as 1.0 mm. Either vitrector may be used with cut rates as high as 2,500 cuts per minute for cutting vitreous.

The Signature phaco system offers dual-pump technology whereby the surgeon may choose to use either a peristaltic or a venturi pump system during the anterior vitrectomy. Venturi pump systems are the industry standard for posterior segment surgeons and may offer advantages over peristaltic pumps during an anterior vitrectomy. Additionally, all the system's vitrectomy parameters are fully programmable (ASP, VAC and CPM) for either linear or panel control. Practitioners may use two vitrectomy submodes: ICA (irrigate, cut, aspirate), which is used in the presence of vitreous; and IAC (irrigate, aspirate, cut), in the case of residual cortex or nuclear fragments that need to be engaged by the vitrector prior to cutting.

Finally, setup for the Signature vitrector is simple and quick. The scrub technician performs an automated, 5-second prime cycle to prime and test the cutter before the surgeon enters the eye.



The WhiteStar 20-gauge high-speed vitrectomy probe.

SUMMARY OF VITRECTOMY PARAMETERS*

- Less flow = less traction
- Select settings to reduce vitreoretinal traction:
 - highest cut rate available
 - flow rate: 20 cc/min for 20-g vitrectomy; 15 cc/min for 23-g
 - lowest vacuum to remove vitreous: 200 to 250 mm Hg for 20-g or 350 to 500 for 23-g; use panel setting, not linear
 - irrigation bottle with 23-g cannula to balance for normotension, about 80 cm

**Note: These settings are for the Alcon system; settings may vary on different machines.*

as high as 5,000 cuts per minute. Faster cutting leads to less traction and a smoother removal of vitreous. Use the fastest cut rate your machine provides. The aspiration rate generally should be 15 to 20 cc/min (this is not independently set on Venturi machines, only peristaltic pumps) (see Summary of Vitrectomy Parameters).

Linear Vs. Fixed Vacuum Setting

Vitreoretinal surgeons who work in the posterior segment every day prefer to use linear vacuum for vitrectomy, because they can control the intraoperative environment. Familiarity leads to facility, so that some physicians can use a graduated foot position 3 with ease. Anterior segment surgeons who perform vitrectomy rarely, however, are not as adept at these maneuvers and often get nowhere, because we are too timid to even venture into foot position 3. Staying in foot position 2 will accomplish nothing, because there will be continuous cutting and no suction. I believe that we anterior segment surgeons should use a panel/linear setting for vacuum instead of a linear vacuum setting for vitrectomy. We want to find and maintain the lowest level of vacuum that moves the vitreous; there is no reason to use higher or lower vacuum once the vitreous is moving. Such linearity allows us to either go pedal-to-the-metal in foot position 3 with suction, or come up into foot position 2 without suction. The vacuum default settings on today's phaco machines are usually set at 150 mm Hg, ideal for primary three-port vitrectomy. In unplanned vitrectomy, however, the anterior segment surgeon is almost always removing vitreous in a sea of dispersive OVD. I find 150 mm Hg to be inadequate in a viscoelastic-filled environment; I generally use 250 mm Hg for 20-gauge and 350 mm Hg for 23-gauge vitrectomy.

Irrigation

We must keep the irrigation bottle moderately high in order to maintain a normotensive eye. Again, the phaco

machine's default setting places the bottle low. The appropriate bottle height depends on the size of cannula we use. Most anterior segment surgeons opt for a 23-gauge cannula. To control the IOP, I have my scrub nurse stand with one hand on the bottle's button, ready to raise it as needed, and one hand on the vacuum button. I start the vacuum for 20-gauge vitrectomy at around 200 mm Hg, and I ask the scrub nurse to progress by 10-mm increments to 250 mm Hg or stop once the vitreous begins to move. As soon as I see movement toward the vitrector port, I have the scrub nurse raise the bottle to prevent a soft eye. We continue in this manner until we reach homeostatic normotension.

GETTING STARTED

Vitrectomy Mode and Incisions

The first step is to confirm initial vitrectomy mode settings and then irrigate any bubbles out of the irrigation line while the vitrector is outside the eye. If choosing an anterior approach, make a second paracentesis a little less than 180° away from the original sideport, large enough to fit the bare vitrector needle. If you are planning to make a pars plana incision under topical anesthesia, make sure to first place a bleb of lidocaine with epinephrine sub-tenons over the intended area of the incision for the patient's comfort. This step permits a small, fornix-based peritomy to bare the sclera without cautery (Figure 8).

Next, secure the primary wound if there is no vitreous loss. If vitreous is incarcerated in the incision, blocking a watertight closure, then fill the anterior chamber with OVD to approximate normal pressure. Avoid making the scleral incision at 3, 6, 9, and 12 o'clock so as to miss the ciliary vessels and nerves. Use a caliper to measure 3.5 mm posterior to the limbus in the quadrant most convenient to your

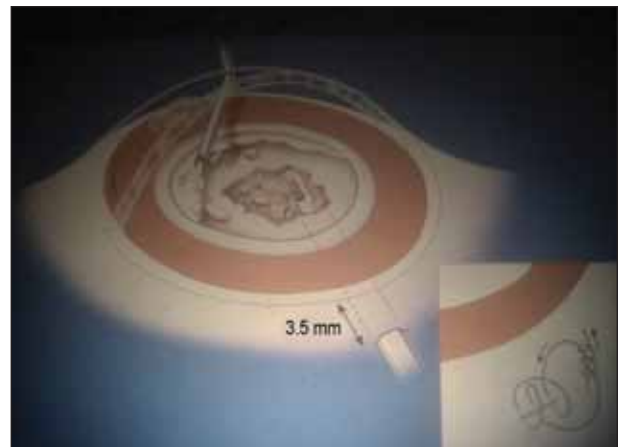


Figure 8. This image shows the biaxial vitrectomy approach, with irrigation through a clear corneal incision and the vitrector entering through a pars plana sclerotomy 3.5 mm posterior to the limbus. A double-bite mattress or X suture with an 8-0 vicryl is used to close the direct-approach sclerotomy.

dominant hand, and avoid perforating vessels. Enter the pars plana with an MVR blade directed toward the optic nerve or the center of the eye until you can visualize the blade in the pupil and withdraw the blade. Insert the irrigating 23-gauge chamber maintainer or a cannula through the original clear corneal incision paracentesis.

Vitrectomy

Insert the vitrector through the sclerotomy and view it in the center of the iris through the pupil. Always make sure you can see the port during vitrectomy; the only exception is when performing a dry vitrectomy to make space in a crowded anterior chamber. In this scenario, make sure the port is sideways or backwards to avoid engaging the posterior capsule while removing a small amount of vitreous.

Remain in foot position 0 to this point. The moment you can see the vitrector's port, go to foot position 2, which will cause irrigation and activate the cutter without allowing vacuum to build. You can now advance the cutter to the center of the pupil below the broken posterior capsule and start aspirating vitreous by engaging foot position 3. Watch for any small bubble or particle to confirm that the vacuum is high enough to move vitreous, and raise the vacuum slowly until you can visually confirm the movement of vitreous into the vitrector port. If you have set the vacuum on panel or fixed rather than linear, you can put the pedal to the metal and ask the scrub nurse to raise the vacuum slowly until it effectively begins to aspirate vitreous, usually at approximately 250 mm Hg for 20-gauge or 350 mm Hg for 23-gauge vitrectomy. As soon as you see effective aspiration taking place, you must raise the bottle to achieve homeostasis

for a normotensive globe. The scrub nurse will also adjust this parameter on the fly and usually will find homeostasis at about 70 to 80 cm, depending on where the patient's head is relative to the machine's cassette. As noted, the flow rate on machines with a peristaltic pump usually stays at 20 cc/min for 20-gauge and 15 cc/min for 23-gauge vitrectomy, and it need not be adjusted.

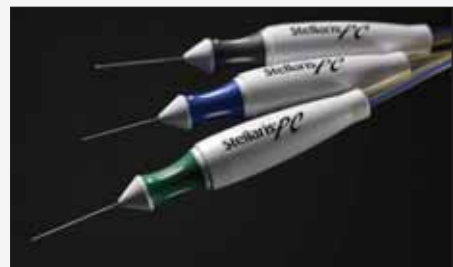Completing Vitrectomy

Keep the pedal to the metal until it is evident that there is no more prolapsed vitreous flowing to the port. If you must move the position of the vitrector, change from foot position 3 to 2 in order to cut with no suction, and then readjust the location of the port to address any other areas of vitreous prolapse. Do not move the vitrector around through vitreous without being in foot position 2 to avoid inadvertent traction.

When you think you have reached the end, hold the vitrector still and come to foot position 0. Remove the irrigation cannula, and irrigate some diluted Triesence into the anterior chamber. Again place the irrigator through the paracentesis to disperse the Triesence, thereby confirming the complete absence of prolapsed vitreous. When extracting the vitrector from the eye, remain in cutting mode (foot position 2) until you have lost visualization under the iris. Come up into foot position 1 for the brief interval that the vitrector is between the edge of the iris and when it exits the sclera, but go to foot position 0 right before you exit the incision, so as not to blow vitreous out of the incision. Retinal surgeons will continue irrigating until they are out of the eye, but that is because they have done a total vitrectomy. When cleaning the sclerotomy of any prolapsed vitreous, turn the cutter down

THE STELLARIS PC VITRECTOMY SYSTEM

The Stellaris PC Vision Enhancement System (Bausch + Lomb) features next-generation vitreoretinal surgical technology in the form of an ultra-high-speed cutter and the familiar lightweight microvit-style handpiece. With an optimized duty cycle, the port of the handpiece is open at least 50% of the time, even at 5,000 cpm. This allows surgeons to effectively remove vitreous at even the highest cut rates. Using the lightweight pneumatic cutter and 5,000 cpm with an optimized duty cycle, surgeons may control the flow intuitively via the foot pedal. The programmable foot pedal is wireless and has Dual-Linear control, which enables the surgeon to vary the vacuum and cut rate. The vacuum on the Stellaris PC is controlled by an advanced algorithm that produces accurate, smooth, and linear aspiration that remains predictable at vacuum as low as 2 mm Hg. If the vitrectomy technique involves a pars plana approach, the trocar tip's long taper provides sufficient cutting surface. This tip is designed to permit a shallow angle of entry during tunnel incisions. The trocar's needle has been redesigned to be solid instead of hollow, which reduces the force of the insertion and displaces less tissue.



The Stellaris PC ultra-high-speed vitrectomy probe.

toward the external lips of the wound while irrigating externally onto the incision, and sharply cut away any external strands before suturing. Never use a Weck-Cel sponge.

Immediately place a scleral plug or a temporary tie suture to close the sclerotomy. If you used an anterior approach, confirm that the clear corneal incision closes and that no strand of vitreous has followed your withdrawal of the vitrector needle. The eye is now closed and ready for further maneuvers, and the vitrectomy site is available in case vitreous presents again.

Wecking and Sweeping Incisions

For generations, ophthalmic residents were told to use a cyclodialysis spatula to sweep from the paracentesis to just inside the main incision to identify, release, and remove incarcerated vitreous. This practice causes significant traction on the posterior vitreous and should be abandoned, in my opinion. The preferred technique is particulate identification and sharp cutting or, ideally, using a vitrector to amputate connections posteriorly at the pupil margin (thus obviating the need for traction). Once the vitreous sheet either retracts to the posterior segment or is severed from the vitreous within the wound, it is safe to remove residual vitreous from the incision with a Weck-Cel sponge. Sponges should never be used to remove vitreous that is still attached posteriorly, however, because they absorb vitreous strands and lead to traction and cause inflammation upon contact with iris tissue. Any time you touch a sponge to the incision, have scissors ready in the other hand so that, should you discover vitreous, you can cut it without lifting or stretching the strands. Immediately cut off the vitreous at the plane of the sclera so that you do not pull it forward out of the wound. Then, you may address the vitreous in the optimal manner.

SUTURING OF DIRECT SCLEROTOMY (20- OR 23-GAUGE)

Older-style vitrectors had a flat tip that required an opening slightly larger than their gauge. The vitrector on the INFINITI Vision System (Alcon Laboratories, Inc.), which I use, has a rounded tip that makes the incision requirement true to size and its entry less traumatic.

Closing a 20-gauge sclerotomy requires a two-bite incision. A 23-gauge direct MVR incision may require only one bite to be watertight. Prior to suturing the sclerotomy, irrigate the lips of the incision while using the vitrector in foot position 2 (cutting) to clear any incarcerated strands of vitreous. Or, shear any vitreous within the sclerotomy with scissors. Never use a cellulose sponge at a pars plana sclerotomy. Then, I prefer to make an X or a mattress suture of 8-0 Vicryl (Ethicon, Inc.). It may be best to orient the needle from a posterior to anterior position when taking the 1/2 thickness bite to ensure that the needle's point does

not come out too far posteriorly. It is not necessary to bury the knot, as it will be covered by the Tenons and conjunctival fornix-based flap that you will suture in place with the same absorbable suture. Tie the knot on the inside of the flap for the patient's comfort (Figure 9). The sclerotomy should be watertight, and no bleb should form from pressurizing the globe.

SUTURELESS VITRECTOMY (23- OR 25-GAUGE TROCAR CANNULA SYSTEM)

Because we want a noncoincident incision in the conjunctiva and the sclera, it is difficult to make a sutureless incision without the help of a cannula to keep the two openings lined up. Finding the openings with the vitrector via an MVR blade-created shelved entry is very challenging. The cannula is a hollow tube that often encases a sharp MVR blade. You withdraw the blade once you have completed the incision, but the tube remains as a conduit for the vitrector needle, which you can repeatedly insert as needed until the case is completed.

A trocar cannula system offers another advantage. Because it protrudes into the vitreous cavity, the vitrector probe never gets close to the retinal surface, as it does when inserted through a bare sclerotomy. This design provides a margin of safety upon entry and exit. As they become sharper and require less pressure for entry, trocars will be the entry method of choice.

Using a trocar cannula system requires a firm, intact eye with closed incisions to handle the pressure applied to the globe upon entry. If incisions are already present, do not simply close them with hydration, but suture them closed, because the force of inserting the trocar will likely cause iris prolapse if they are not entirely secure. A soft eye will risk choroidal detachment or hemorrhage with this procedure. If vitreous has been lost, you will not be able to close the incisions, even with sutures, so a direct MVR entry with suturing would be safest.

Fill the eye with BSS or OVD until it is firm, while ascertaining that the cataract incisions are closed. Pull the

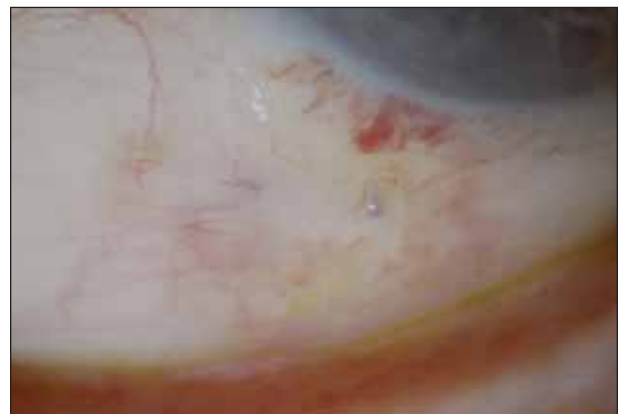


Figure 9. A suture under the conjunctival flap.

conjunctiva away from the site of puncture 3.5 mm back from the limbus and initiate a partial-thickness scleral tunnel with the trocar parallel to the limbus. Travel 2 mm, then turn the device perpendicular to the sclera and puncture the sclera in the direction of the optic nerve, driving the trocar cannula system through the eye wall. Once the trocar is in place, remove the MVR blade and leave the seated cannula for the vitrector's insertion.

Dr. Charles does not recommend a 25-gauge vitrector for anterior vitrectomy, because he says it is too flexible to use without akinesia (topical anesthesia). My experience is with 20- and 23-gauge vitrectors only (see Pars Plana Instrumentation).

RESIDUAL CORTEX REMOVAL

- Perform a “dry technique” under OVD without irrigation
- Bimanual I/A imparts a small risk of incarcerating vitreous
- Use the vitrector on I/A-Cut mode (not I-Cut-A default) for followability
- Coaxial I/A not recommended unless optic is captured
- Prevent chamber collapse during removal of instruments: vitreous will follow the path of lowest pressure and present again

Once you have removed the vitreous and lens particles, you are left with cortex. It is incumbent upon us to clean the capsular fornix thoroughly to avoid inflammation,

prevent a poor-quality view with fluffed cortex in the post-operative period, and ultimately to reduce the risk of CME. We have three viable options to accomplish this goal.

The safest way to clean the capsular bag (albeit, not the most efficient) is to empty it with a dry technique. This means maintaining and expanding the chamber and the capsular fornix with cohesive viscoelastic and packing in the dispersive agent to cover the capsule or the zonular defect. Without irrigation, use a 3- or 5-mL syringe with a 26-gauge cannula (or a Simcoe cannula system) to suction out residual cortex. There should be just enough BSS in the syringe to be able to reflux in case the capsule or vitreous become incarcerated. When the tip is occluded with cortex, a manual application of suction strips it cleanly away if the anterior leaflet leads. A 23-gauge cannula is useful for dense cortical or epinuclear material, but we must be careful not to attract the capsule into the port's opening where it will rip. Replace the cohesive OVD as needed to keep the capsular fornix expanded and the eye normotensive as cortex removal proceeds. This technique avoids the risk of displacing more vitreous with irrigation and inviting it forward, or pushing fragments to the back of the eye.

Another way to remove residual cortex is via bimanual I/A. Some surgeons prefer this strategy because of its efficiency. Bimanual I/A is a much better approach for removing residual cortex than coaxial I/A, which involves irrigating in the same area from where you are trying to remove the cortex. The biaxial approach conducts the irrigation anteriorly, which continues to encourage vitreous to stay back. You can direct the separate aspiration into the cortex and keep it fully occluded. Use a second sideport paracentesis with this technique so the chamber remains watertight with a closed main clear corneal incision. Although unlikely, if you encounter vitreous, there will be a tractional event that you can mitigate by immediately stopping aspiration while holding the aspiration handpiece steady, exchanging the irrigation handpiece for an intraocular scissors, and cutting the incarcerated vitreous strand. This strategy will relieve the traction before you withdraw the aspiration handpiece and have to deal with the prolapsed vitreous again with vitrector.

A safer technique than bimanual I/A is to use the vitrector on a different setting. Every phaco machine has a different way to switch from irrigation-cut-aspiration, which must always be used for vitreous, to irrigation-aspiration-cut. The point is to discourage followability when removing vitreous, although followability is necessary for removing cortex. Using the vitrector on I-cut-A mode does not work for removing cortex, because it continually chops it off and never allows the cortex to flow into the port. Because you cannot strip it out of the sulcus, you end up following the cortex into the sulcus and eating capsule. If you switch to I-A-cut mode, then

PARS PLANA INSTRUMENTATION

Pars Plana Instrumentation

- Standard 20-gauge
 - Readily available
 - Conjunctival flap
 - Sutured incision
- 25-gauge
 - Too flexible for topical anesthesia
- 23-gauge
 - Sutureless with excellent sealing if oblique incision
 - Trocar cannula optional, direct 23-gauge MVR entry preferred if the globe is not intact

A trocar requires more pressure to insert than a direct MVR blade and should only be used when incisions can be closed with a normotensive or firm eye. For a sutureless incision, a limbal parallel circumferential scleral tunnel precedes the perpendicular entry into the vitreous cavity. The conjunctiva is pulled aside so the conjunctival entry wound is not coincidental with the scleral entry.

you can remove the cortex in foot position 2 when you are sure the vitreous is out of the way. If you think vitreous has emerged, you can immediately go down to foot position 3 and cut it off. This approach is safer than I/A in that it relieves a tractional event instantly. Finally, make sure to prevent the chamber from collapsing while you remove the instruments after a vitreous prolapse, an open hyaloid, or even just an open capsule.

IMPLANTING AN IOL

Inspect Prior to Implantation

To make sure the anterior segment is cleaned of all cortex, you may need to retract the iris to fully view the bag fornix. Reinstill Triesence and then rinse it away to be sure there is no vitreous present. Check that the pupil is round and that the incisions are sealed. Verify the status and size of the capsulorhexis, and evaluate the extent of the posterior capsular tear and whether there is a true continuous curvilinear tear. Be aware of any retained nuclear fragment below the posterior capsule, and make certain no fragments are hiding anteriorly under the iris or subincisionally.

IOL Selection and Placement

When there is an uncontrolled break in the posterior capsule but the anterior CCC is intact, I advocate implanting a three-piece lens in the sulcus and capturing the optic through the anterior capsulorhexis. Only when the posterior tear is converted to a true PCCC will I place any IOL (ideally, a single-piece one) in the capsular bag. Regardless of its location, shape, or size, an unconverted rent may extend in response to even minor pressure. If the PCCC is 4 to 5 mm and centrally located, then we can place a three-piece lens in the bag and perform an optic capture through the PCCC into Berger's space. This is the ideal outcome.

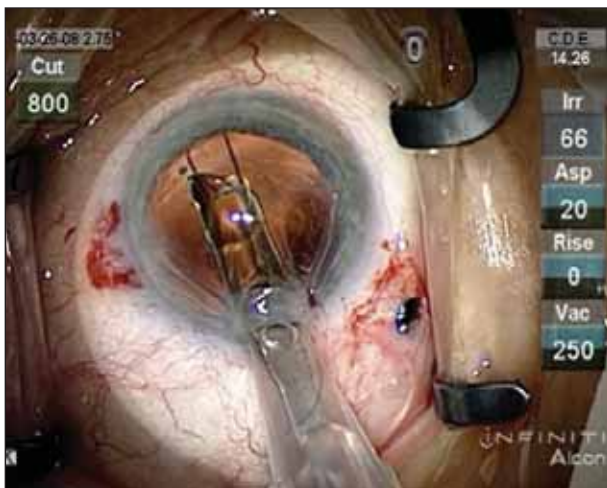


Figure 10. In the optic capture technique, the author directs the IOL's leading haptic into the sulcus.

IOL IMPLANTATION CHOICES FOLLOWING A POSTERIOR CAPSULAR RUPTURE

- Three-piece IOL in the bag, optic-captured through the posterior CCC into Berger's space
- Single-piece IOL in the bag
- Three-piece IOL in the sulcus, optic-captured through the anterior CCC
- STAAR AQ sulcus-supported three-piece IOL, free-standing in the sulcus
- Foldable three-piece PC-IOLs must be sutured to the iris and not left free-standing in the sulcus (a personal practice technique)
- Scleral-sutured IOL (my least preferred option)
- Anterior chamber four-point fixation, open-looped, modern IOL with peripheral iridectomy
- Aphakia

If there was a zonular break in the presence of an intact posterior capsule and an intact anterior capsulorhexis with a stable and centered bag, I will use a standard or modified capsular tension ring or a capsular tension segment sutured to the sclera.

If the posterior capsule is intact but there is a break in the anterior capsulorhexis, I will place a single-piece IOL in the bag (as long as I know the haptics will stay sequestered in the bag and not pop out into the sulcus).

The Optic Capture Technique

Whenever possible, we should choose an optic-capture strategy that always produces a centered, stable lens. This is the reason I advocate making a CCC smaller than the intended optic in every case, and why I work so hard to maintain the anterior capsulorhexis after breaking the posterior capsule. I use the well-known optic-capture technique described by Howard Gimbel, MD,⁵ in which the sulcus is defined with OVD and the capsular bag is left uninflated. I inject the three-piece lens with the leading haptic clearly placed in the sulcus (Figure 10). I pronate the trailing haptic into place with a two-handed technique (dialing can be risky) that minimizes displacement of the optic and stress on zonules. I place mild pressure on the optic 90° away from the haptic-optic junction to dunk the edge under the capsulorhexis on one side and then the other, allowing the capsulorhexis to become ovoid. With very loose zonules, this may require a two-handed technique of lifting the bag gently while sweeping under the edge of the capsulorhexis and simultaneously applying downward pressure to the optic. The end result leaves the haptics secured in the sulcus and the optic in the bag.

If the capsule breaks after the IOL is in the bag, a less traumatic but not widely tested alternative to IOL

exchange is the forward optic capture technique. You may use the optic-capture concept to your advantage by forward-capturing the optic in front of the intact capsulorhexis while leaving the haptics in the bag (*a personal practice technique also described by Howard Gimbel, MD*).

If neither the anterior capsulorhexis nor the posterior capsule is intact, you must decide between implanting a standalone or sutured sulcus-fixated IOL or a modern anterior-chamber implant. In my opinion, it is important to secure any IOL that is not a true sulcus-supported lens (the only such lens that currently has FDA approval is the AQ series from STAAR Surgical Company). Single-piece IOLs are incompatible with sulcus fixation. The clinical study of the AcrySof natural single-piece lens was conducted with the lens implantation in the capsular bag only. There are no clinical data to demonstrate its safety and effectiveness for placement in the ciliary sulcus, and plenty of evidence that it will cause pigmentary dispersion glaucoma by chaffing the posterior iris.⁶ Standard three-piece IOLs are too small for the sulcus. They will move around and cause inflammation, CME, and pigment dispersion in a significant number of eyes. Liliana Werner, MD, PhD, has shown that the size of the sulcus varies. It is not proportional to axial length or white-to-white measurements, and it is often larger than 12.5 or 13.0 mm, which is the haptic diameter of a standard three-piece lens. Furthermore, if there is a little hole in the posterior capsule or particularly in the zonules, the sulcus-implanted lens will eventually find its way through it. Having practiced for almost 30 years, I have seen this complication on referral many times. You can purchase the STAAR lens (available in the United States) for inventory. It is made of biocompatible silicone with a rounded edge. The lens' stiff elastimide haptics are 13.5 mm apart, making it our only reliable choice for unsupported sulcus implantation.

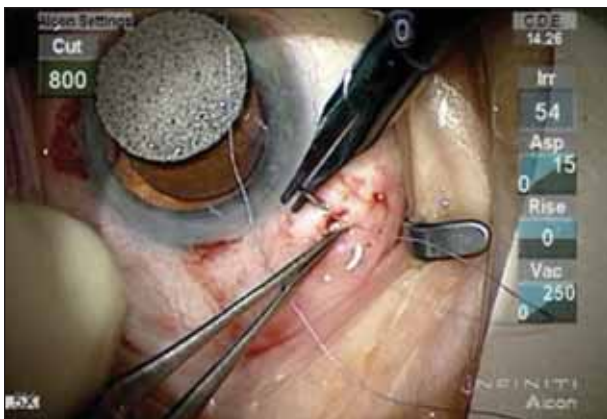

Figure 11. A suture is always placed in the direct entry sclerotomy. Plan to also suture the cataract incision if there is the possibility of retained lens material that may necessitate a secondary retinal procedure.

It is your choice whether to anchor a standard three-piece IOL in the sulcus with one or two iris sutures or place a PMMA lens with eyelets as a scleral-sutured lens. (I believe the glued scleral-fixated method has not yet stood the test of time.) In the presence of no intact anterior or posterior capsule, especially after a long case, my preference is to place an anterior-chamber lens through a scleral tunnel, having closed my clear corneal incision. In this scenario, I make a peripheral iridectomy with the vitrector. After instilling Miochol E, I use I/A/Cut mode with raised vacuum and a lowered cut rate to produce a neat peripheral hole in the iris before I place the IOL (taking care to not tuck the iris). 'White-to-white plus one' is still the standard for sizing the IOL in this maneuver. A review of the ophthalmic literature shows that there is no decrease in the quality of long-term outcomes with implanting IOLs in the anterior chamber versus suturing them in the posterior chamber.

REMOVING OVD AND CLOSING THE EYE

If you do not capture the optic in an eye that has lost vitreous, then be very cautious in removing the viscoelastic at the end of the case. I usually do this manually in these eyes by irrigating and then slightly burping the incision to let some of the OVD out. I irrigate some more, and then I use a manual push/pull technique through the paracenteses to remove all of the viscoelastic that I reasonably can. Be careful not to lower the pressure in the anterior chamber by overzealously removing the viscoelastic, thereby allowing vitreous to re-present. Of course, you can remove the viscoelastic more aggressively if you have used an optic-capture technique. I prefer not to use Healon5 (Abbott Medical Optics Inc.) in complicated cases, because even a little of this OVD left behind can cause a severe rise in IOP in the postoperative period. VISCOAT OVD is the most forgiving agent, since it is of a smaller molecular weight. Any OVD that remains behind a properly captured optic is of no concern, as it will not have access to the trabecular meshwork and will slowly be absorbed without incident.

Miochol E (acetylcholine) will provide miosis, protect the IOL's position, and ensure a round pupil with no peak, which would indicate a vitreous wick.

A final minim of Triesence and rigorously closed incisions with dry tunnels will confirm that no incarcerated vitreous is lurking. Even if the clear corneal incision seals flawlessly, a suture is indicated (Figure 11) if a follow-up retinal procedure may be needed due to retained lens material.

Before I exit the eye, I like to make sure the pupil is well rounded and not stuck anywhere or held back by vitreous. So, I instill Miochol-E and watch the pupil come down (*see Pharmacology*). Then, because a break the vitreous face significantly increases the risk of endophthalmitis, I always prophylax the eye with intracameral moxifloxacin (an off-label use).⁷ Immediately postoperatively, I provide one dose of

PHARMACOLOGY

- Miochol-E
- Antibiotic prophylaxis with intracameral moxifloxacin and Avalox 400 mg, PO prior to discharge (my choice, though off-label)
- Anti-inflammatory: topical NSAID beyond 1 month and a long taper of steroid
- Hypotensive meds: Diamox (if no sulfa allergy)

POSTOPERATIVE FOLLOW-UP

- Warn patients to expect floaters
- Prophylax and treat any pressure spikes
- If the sclera is indented, a scleral indented retinal examination and/or retinal consultation are mandatory
- Close monitoring for CME
- Disclosure to patients

Avalox (Bayer Corporation), which is a systemic form of moxifloxacin (400 mg P.O.) that crosses the blood-retinal barrier.

Furthermore, patients with open posterior capsules need to use a longer taper of topical steroid than routine patients and remain on topical NSAIDs for a longer period (off label) to prevent CME. Hypotensive medications are also a good idea, because we often leave some viscoelastic behind, and these eyes often experience a postoperative rise in IOP. I prescribe Diamox (Wyeth Pharmaceuticals) if there is no history of sulfa allergy (10% of people who have sulfa allergy are allergic to Diamox), and then I carefully follow the patient postoperatively.

CONCLUSION

Warn vitrectomy patients to expect floaters postoperatively and to call and identify themselves as surgical patients if they experience pain or decreasing vision at any time (see Postoperative Follow-Up). Treat any IOP spikes aggressively and follow them closely, especially over the first 48 hours. Teach patients to check their peripheral vision at home. I highly recommend performing a scleral indented retinal examination and/or a retinal subspecialty consultation within 1 to 2 weeks after the surgery to be absolutely sure there are no holes or tears in the peripheral retina that need to be treated. Closely monitor these patients for CME with an Amsler grid at home. Also, optical coherence tomography is indicated. Often, vitrectomy patients can achieve 20/20 UCVA on the first postoperative day, and the floaters will disappear with time. It is critical to inform these patients of their increased risk of developing a retinal tear or detachment in the future, in addition to the increased risk of glaucoma and CME. Educate these individuals about the signs of a retinal tear or detachment so they may be vigilant for them, and inform them of the need for periodic testing for glaucoma. Finally, if an eye has retained lens

material, then you must refer the patient to a retinal specialist in a timely fashion for a possible definitive treatment. A recent meta-analysis of the literature shows patients fare best if the intervention is from 3 days to 7 days after surgery that was complicated by retained lens material.⁸

When we prepare in advance for a loss of vitreous with a comprehensive strategy and we treat the patient with logic and care, we can often achieve optimal outcomes, even in complicated cataract cases. ■

Lisa B. Arbisser, MD, is in private practice with Eye Surgeons Assoc. PC, located in the Iowa and Illinois Quad Cities. Dr. Arbisser is also an adjunct associate professor at the John A. Moran Eye Center of the University of Utah in Salt Lake City. She acknowledged no financial interest in the products or companies she mentioned. Dr. Arbisser may be reached at (563) 323-2020; drlisa@arbisser.com.

The author wishes to thank Steve Charles, MD, for his inspiration and guidance and for sharing his vast knowledge. She also thanks her partner, Michael Howcroft, MD, for his support and ongoing teaching efforts. Additionally, the author wishes to thank the following individuals for their time and contributions to teaching: Amir Arbisser, MD; Brian Berger, MD; Scott Burke, MD; Doug Fanny, PhD; Howard Gimbel, MD; Ricardo Glikin, MD; Rupert Menapace, MD; Anita Nevyas-Wallace, MD; Aron Rose, MD; Kevin Waltz, OD, MD; and Liliana Werner, MD, PhD.

Finally, she thanks her many peers and mentors who have helped to teach the skills transfer labs: Alan Aker, MD; Francis Applegate, MD; Rosa Braga-Mele, MD; Jorge Calzada, MD; James A. Davison, MD; Luther L. Fry, MD; Harry B. Grabow, MD; Warren E. Hill, MD; Michael J. Howcroft, MD; Jay I. Lippman, MD; Cathleen M. McCabe, MD; Kevin Miller, MD; Anita Nevyas-Wallace, MD; Kenneth J. Rosenthal, MD; Jack A. Singer, MD (deceased); Michael E. Snyder, MD; Dee Stephenson, MD; Jeffrey Whitman, MD; and Richard Tipperman, MD.

For further reading:

1. Arbisser LB. Anterior vitrectomy for the anterior segment surgeon. Focal points. The American Academy of Ophthalmology; March 2009.
2. Arbisser LB, Charles S, Howcroft M, Werner L. Management of vitreous loss and dropped nucleus during cataract surgery. *Ophthalmol Clin North Am.* 2006;19(4):495-506.
3. Lincoff H, Zweifach P, Brodie S, et al. Intraocular injection of lidocaine. *Ophthalmology.* 1985;92(11):1587-1591.
4. Osher RH. Slow motion phacoemulsification approach. *J Cataract Refract Surg.* 1993;19(5):667.
5. Arbisser LB, Charles S, Howcroft M, Werner L. Management of vitreous loss and dropped nucleus during cataract surgery. *Ophthalmol Clin North Am.* 2006;19(4):495-506.
6. Spence DJ, Peyman GA. A new technique for the vital staining of the corneal endothelium. *Invest Ophthalmol.* 1976;15(12):1000-1002.
7. Gimbel HV, DeBroff BM. Intraocular lens optic capture. *J Cataract Refract Surg.* 2004;30(1):200-206.
8. Chang DF, Masket S, Miller KM, et al; ASCRS Cataract Clinical Committee. Complications of sulcus placement of single-piece acrylic intraocular lenses: recommendations for backup IOL implantation following posterior capsule rupture. *J Cataract Refract Surg.* 2009;35(8):1445-1458.
9. Arbisser LB. Safety of intracameral moxifloxacin for prophylaxis of endophthalmitis after cataract surgery. *J Cataract Refract Surg.* 2008;34(7):1114-1120.
10. Vanner EA, Stewart MW. Vitrectomy timing for retained lens fragments after surgery for age-related cataracts: a systematic review and meta-analysis. *Am J Ophthalmology.* 2011;152(3):345-357.

