

# SubCyclo: A New Treatment Option for Advanced and Refractory Glaucoma

BY PIETER GOUWS, MBCHB, FRCOPHTH



Origins of surgical glaucoma treatment date back to the mid 1800s when iridectomy was discovered as an effective surgical method for the treatment of acute glaucoma and sclerotomy was presented as a procedure for chronic glaucoma.

Though advancements have continued to change the landscape of how to treat glaucoma, the approaches remain largely the same: relief of the pupillary block, external filtration, internal filtration, and ciliodestruction. The underlying targets in glaucoma treatment are lowering eye pressure, increasing outflow, and decreasing inflow of aqueous humor.<sup>1</sup>

Cyclocryotherapy was among the first treatments for glaucoma and was considered a simple, short, noninvasive surgical procedure to treat advanced, uncontrolled glaucoma. Though it was an important addition to the armamentarium for glaucoma, it was reserved for eyes with the greatest risk and poorest prognosis. In other words, it was used as the very last line of defense, but that is where we started more than a century ago with regards to destructive treatment to the ciliary body.<sup>2</sup> When lasers were introduced, it was initially thought to reserve laser treatment for end-stage conditions where the only option was to simply save the eye itself and stop the pain. As we came to discover, that certainly wasn't the case.

## CYCLODIODE—A VALID TREATMENT FOR REFRACTORY GLAUCOMA, BUT NOT WITHOUT COMPLICATIONS

Cyclodiode has been unequivocally proven as safe and effective treatment of advanced refractory glaucoma. A study<sup>3</sup> to analyze the results of IOP reduction by diode laser contact cyclophotocoagulation in eyes with advanced refractory glaucoma concluded that diode laser cycloablation is relatively safe and

effective. However, despite this, complications such as phthisis, chronic hypotony, and corneal graft decompensation followed treatment in several cases. This was demonstrated in another study<sup>4</sup> investigating the dose-response relation of cyclodiode and evaluating possible predictive factors to help establish optimum treatment parameters. In a retrospective analysis, cyclodiode therapy was found highly effective but with a significant risk of hypotony. Interestingly, it was also discovered that hypotony could be reduced by applying lower energy in cases of very high pretreatment IOP and in neovascular glaucoma.

We can conclude that the use of a continuous-wave diode laser, though initially determined safe and effective, provides suboptimal IOP control, is destructive to the ciliary body, and diminishes aqueous secretion. Much like cyclocryotherapy, transscleral cyclophotocoagulation (TSCPC) has been used as the last option in eyes with preserved function and uncontrolled, severe glaucoma simply because the risk of the patient's eye pressure lowering too far or becoming chronically inflamed is too great.

## SUBCYCLO EFFECTS VERSUS CONTINUOUS-WAVE CYCLODIODE

Despite its benefits, the long-term effects and risks of TSCPC are undeniable. A study<sup>5</sup> found that 51.5% of eyes failed by the end of 10 years, with most failures occurring within the first year (40%). Furthermore, a visual loss of two lines or more occurred in 75% of patients, while phthisis occurred in 3% of eyes, and 7% of eyes with bad vision lost all sight and light perception.

Based on the TSCPC principle, SubLiminal cyclophotocoagulation (SubCyclo) (Quantel Medical) is one of the latest laser procedures for the treatment of primary open-angle glaucoma and closed-angle glaucoma. SubCyclo features a nondestructive 810-nm SubLiminal laser to reduce the production of aqueous humor, selectively destroy the pigmented ciliary body, and undertake uveoscleral remodeling, which increases outflow through the unconventional pathway.

The main difference between the SubLiminal technology available in SubCyclo and continuous wave cyclodiode is the precise management of thermal elevation, which delivers energy in a succeeding train of very short microsecond pulses, with alternative "on" and "off" features (Figure 1). In a direct comparison study,<sup>6</sup> SubCyclo provided more consistent and predictable outcomes with minimal ocular complications. The use of SubCyclo showed no significant differences

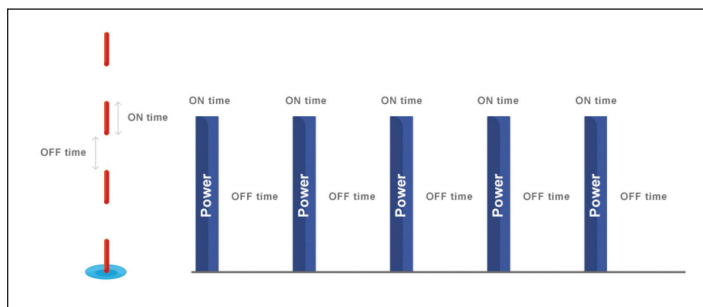


Figure 1. SubCyclo laser therapy: train pulse.

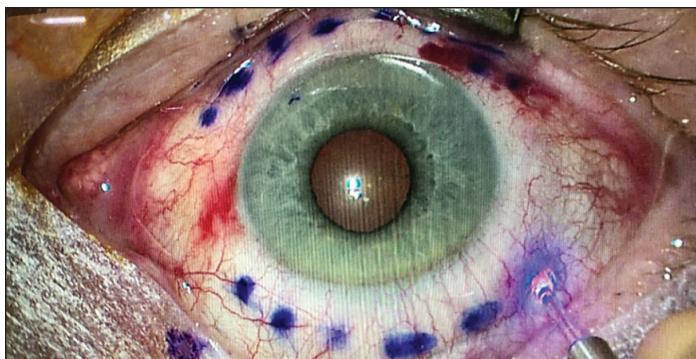


Figure 2. Probe positioning during the SubCyclo treatment.

in IOP reduction, need for retreatment, or decrease of IOP-lowering medication but demonstrated significantly lower complication rates.

### IS SUBCYCLO EFFECTIVE IN REFRACTIVE GLAUCOMA?

Several published studies looking at outcomes of SubCyclo laser procedures are showing comparable, positive results. In a study<sup>7</sup> of 50 eyes of patients with various subtypes of glaucoma, SubLiminal TSCPC was administered with a minimum 6-month follow-up. The mean IOP decreased from the preoperative value of 26.27 mm Hg ( $\pm 6.52$ ) to 15.9 mm Hg ( $\pm 5.72$ ) 1 day after the treatment. The average IOP was 13.72 mm Hg ( $\pm 4.31$ ) at 7 days, 15.81 mm Hg ( $\pm 3.69$ ) at 6 weeks, 15.94 mm Hg ( $\pm 5.66$ ) at 3 months, and 16.32 mm Hg ( $\pm 5.24$ ) at 6 months. Early results showed that SubCyclo delivered a satisfactory IOP reduction with a low risk of complications.

What's interesting is that in a recent literature review<sup>8</sup> of studies involving SubLiminal laser for glaucoma, we can deduce that we've barely scratched the surface on the full effect SubCyclo can have on treatment outcomes. Despite a huge variance of the time that SubCyclo is being administered, there is a high rate of success being demonstrated.

### SUBCYCLO IN A CLINICAL SETTING

An 83-year-old patient presented with 0.9 cupping, a significant cataract, and an IOP of 23 mm Hg in both eyes. I performed a bilateral phacoemulsification and endoscopic cyclophotocoagulation aiming for low pressures, which we achieved at 9 to 10 mm Hg for approximately 3 years. In 2018, her eyes became painful and continued to be so despite a change in medication. I performed selective laser trabeculoplasty (SLT) on both eyes. SLT worked well in her left eye, but her right eye was unchanged and remained at 22 mm Hg at week 4. I decided to perform SubCyclo on the failed SLT eye combining the Vitra 810 laser (Quantel Medical) and the SubCyclo Probe (Quantel Medical) positioning the probe at 3 mm posterior to the limbus and perpendicular to the eyeball (Figure 2).

Treatment settings were established at power level 2W with a 31.3% duty cycle and delivered by moving the tip of the

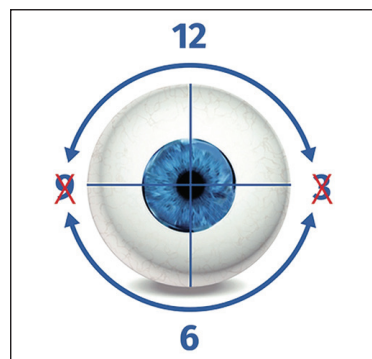


Figure 3. SubCyclo continuous sliding motion.

probe in a continuous sliding motion from the 9:30 to 2:30 clock position (80s superior quadrant) and from the 3:30 to 8:30 clock position (80s inferior quadrant) (Figure 3). Following the treatment, her pressure reduced to 13 mm Hg, drop-free where it remains today. This patient was extremely happy.

### CONCLUSION

Considering the increasing trend these studies and reviews report, it is safe to say that we now have a treatment modality available in SubCyclo with an excellent side effect profile that leaves us to think about how to best use this technology and in which areas we can use this gentler form of treatment. Should we be thinking about SubCyclo on patients where vision is not yet compromised rather than reserving for late-stage treatment? Can we dissolve the use of continuous wave cyclodiode lasers other than for niche treatments such as closing a small cyclodialysis cleft? I think we can confidently answer yes to both.

In August 2019, a study evaluating the outcomes of SubLiminal TSCPC in eyes with good central vision was conducted.<sup>9</sup> At the 1-year postoperative follow-up, SubLiminal TSCPC significantly reduced IOP (40% from baseline) and the use of glaucoma medication (80% of patients having a reduction of  $\geq 1$  medication) without significant reduction in visual acuity. These results encourage the consideration of SubCyclo earlier in the management of glaucoma and could possibly be an alternative to incisional glaucoma surgeries. Ultimately, I think this leaves us with no strong reason to continue using continuous wave cyclodiode as a viable treatment option. ■

1. Razeqhinejad MR, Spaeth GL. A history of the surgical management of glaucoma. *Optom Vis Sci*. 2011;88(1):E39-47.
2. Bellows AR. Cyclocryotherapy for glaucoma. *Int Ophthalmol Clin*. 1981;21(1):99-111.
3. Bloom PA, Tsai JC, Sharma K, et al. Cyclodiode. Trans-scleral diode laser cyclophotocoagulation in the treatment of advanced refractory glaucoma. *Ophthalmology*. 1997;104(9):1508-1519.
4. Murphy CC, Burnett CA, Spry PG, et al. A two centre study of the dose-response relation for transscleral diode laser cyclophotocoagulation in refractory glaucoma. *Br J Ophthalmol*. 2003;87(10):1252-1257.
5. Lin P, Wollstein G, Glavas IP, Shuman JS. Contact transscleral neodymium:yttrium-aluminum-garnet laser cyclophotocoagulation—Long-term outcome. *Ophthalmology*. 2004;111(11):2137-2143.
6. Aquino MC, Barton K, Tan AM, et al. Micropulse versus continuous wave transscleral diode laser cyclophotocoagulation in refractory glaucoma: a randomized exploratory study. *Clin Exp Ophthalmol*. 2015;43(1):40-46.
7. Lutić J, Dragne C, Filip M, et al. SubCyclo laser procedure results in patients with glaucoma. *Rom J Ophthalmol*. 2018 Oct-Dec;62(4):296-299.
8. Ma A, Yu SWY, Wong JKW. Micropulse laser for the treatment of glaucoma: a literature review. *Surv Ophthalmol*. 2019;64(4):486-497.
9. Varikuti VNV, Shah P, Rai O, et al. Outcomes of micropulse transscleral cyclophotocoagulation in eyes with good central vision. *J Glaucoma*. 2019;28(10):901-905.

### Pieter Gouws, MBChB, FRCOphth

- Consultant Ophthalmic Surgeon, Spire Sussex Hospital, The Ridge, Saint Leonards-On-Sea, United Kingdom
- [contact@pietergouws.co.uk](mailto:contact@pietergouws.co.uk)
- Financial disclosure: Lecture fees (Quantel Medical)