

Understanding Total Corneal Astigmatism

Cassini Corneal Shape Analyzer aims to provide better analysis of the entire cornea for astigmatism management.

BY DOUGLAS D. KOCH, MD

This article is based on presentations given at the 2014 summer symposium of the American-European Congress of Ophthalmic Surgery. For more information about Cassini, visit <http://i-optics.com/products/cassini>. Details about AECOS may be found at www.aecosurgery.org.

In recent years, it has become obvious to my colleagues and me that we need better measurements of the entire cornea to ensure precise IOL selection and placement.

Most ophthalmologists would agree that topographic imaging of the anterior corneal surface is critical to achieving the best outcomes for today's cataract patients. Such imaging can reveal corneal irregularities that may indicate risk factors for keratoconus or other pathology about which the patient should be advised before proceeding with surgery.

A few studies, some dating as far back as to Javal in the 1890s, have indicated that some other portion of the eye's optical system plays an important role in determining total ocular astigmatism. My colleagues and I have found the posterior cornea to be a key factor. To better understand the impact of the posterior cornea and its role in astigmatic correction, we conducted a population-based study in our practice. Findings of the study revealed that many of our patients had posterior corneal astigmatism, confirming that the whole corneal picture is indeed necessary for the accurate diagnosis and correction of corneal pathology.

I think the Holy Grail for our surgical patients in predicting astigmatic outcomes is to have a device that accurately measures the front and the back of the cornea so we have a whole corneal picture. If we can couple those data with knowledge about our surgically induced astigmatism, I think we can be extremely precise in the kind of astigmatic planning and corrections that we do.

RAY-TRACING TO PROVIDE BETTER DATA

The Cassini Corneal Shape Analyzer (i-Optics) is a new desktop device designed to measure anterior and now posterior corneal curvature to create a complete picture of the cornea (Figure 1). Cassini uses multicolor LED ray-tracing technology to provide an accurate assessment of the anterior surface of the cornea. This technology captures radial and circumferential measurements with an accuracy of less than 2 μm , which results in precise corneal

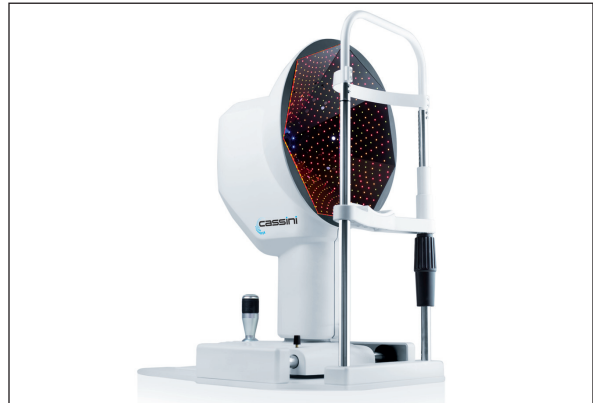


Figure 1. Cassini Corneal Shape Analyzer.

axis measurements to within 3°. It is accurate to within the central 0.8 μm , leaving no space for central scotoma.

Perhaps the most exciting innovation is the Total Corneal Astigmatism (TCA) functionality now available to assess anterior and posterior astigmatism. Using ray-tracing of the second Purkinje reflection off of the back surface of the cornea, Cassini provides calculations for both the degree and magnitude of astigmatism. The anterior and posterior information is analyzed, providing a total corneal astigmatism measurement (Figure 2).

The reflective technology used by the Cassini is truly unique, and it offers the possibility of accurate and repeatable posterior corneal measurements. In my opinion, this may give us the critical measurements of true corneal astigmatism, front and back.

SURGICAL PEARLS TO CORRECTING ASTIGMATISM DURING CATARACT SURGERY

To achieve optimal correction of astigmatism, there are several pre- and intraoperative details we must consider.

Preoperatively, it is best to capture at least two measurements of astigmatism, one of which must be topographic. My colleagues and I have had particular success using the Cassini to determine the magnitude and meridian of the corneal astigmatism from the anterior corneal surface. It has been my go-to device for that particular measurement because of its reproducibility.

One of the key elements of accurate surgical outcomes is the registration of ocular landmarks and the visual axis. The Cassini registers and digitally records

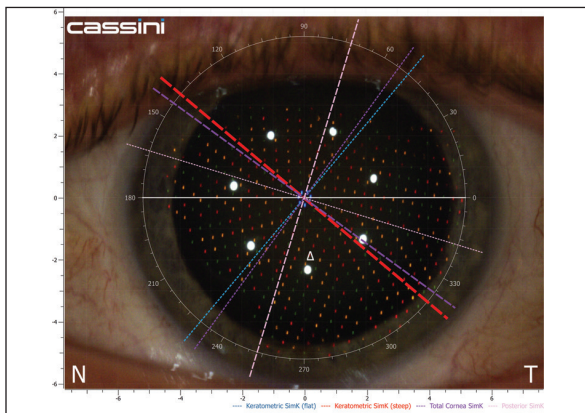


Figure 2. TCA functionality provides surgeons with the total corneal axis and magnitude of astigmatism.

conjunctival features and vessels, as well as the exact location of the visual axis and the magnitude of astigmatism. These data can then be transferred to other technologies such as surgical guidance systems, or printed out at the time of surgery.

Intraoperatively, the Cassini can link to real-time eye tracking systems to assist with the proper alignment and positioning of the incisions and IOL. Locating the corneal landmarks preoperatively and nailing them intraoperatively is, in my view, the best way to optimize toric IOL alignment. ■

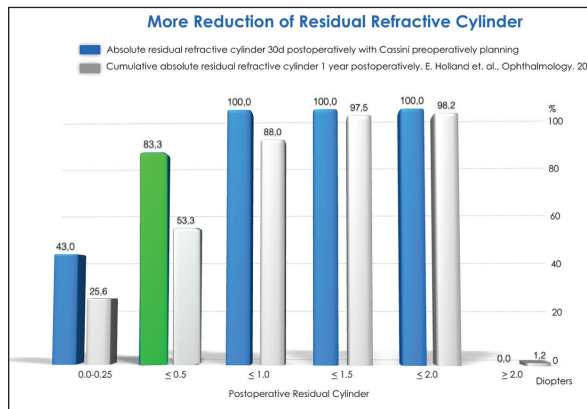


Figure 3. A total of 30 patients (age, 43 to 85 years) with varied preoperative refractive status (astigmatism between 0.50 D and 3.50 D) underwent cataract surgery with toric IOL implantation performed by Dr. Solomon. The Cassini Color LED corneal analyzer was used for preoperative evaluation.

Douglas D. Koch, MD, is a professor and the Allen, Mosbacher, and Law chair in ophthalmology at the Cullen Eye Institute of the Baylor College of Medicine in Houston. He acknowledges no financial interest in the product or company mentioned herein. Dr. Koch may be reached at (713) 798-6443; dkoch@bcm.edu.



CASSINI: IMPACT ON OUTCOMES

By Jonathan Solomon, MD

The investment one makes as a surgeon in preoperative data assessment and intraoperative data analysis is critical. Surgical data are the foundation for ensuring high-quality outcomes, because we are able to achieve a high-level understanding of the refractive surfaces.

The i-Optics Cassini can generate high degrees of repeatability and reproducibility in two critical aspects: axis identification and true corneal power. The device combines the benefits of traditional topography with elevation mapping and ray-tracing to provide a better understanding of the true state of corneal disease.

The ability to use the Cassini in conjunction with other technologies, including femtosecond laser-assisted cataract surgery or 3-D intraoperative imaging and guidance, takes us to a new level in refractive surgery.

The Cassini's ability to transfer a robust image of the eye to a femtosecond laser and then project that image into a 3-D format with appropriate overlays means that the device automates the most challenging aspects of astigmatic correction for more predictable and reproducible results. The Cassini allows us to look at a patient's eye in a preoperative state and accurately predict the surgical outcome. It also allows for a repeated and reproducible image of the postoperative cornea.

In our practice, my staff and I have been following a

small subset of patients who underwent surgery after Cassini-generated imaging. More than 83% of these individuals have less than 0.50 D of postoperative astigmatism—the gold standard for astigmatic correction (Figure 3). I expect that percentage to ultimately become even higher as the Cassini's new Total Corneal Astigmatism functionality becomes available in October.

Some surgeons may question the need for this device, but I feel the Cassini improves our overall understanding of the corneal refractive surface, which was the biggest challenge for surgeons as indicated in a recent *Journal of Refractive Surgery*.¹

In my opinion, the i-Optics Cassini offers high degrees of accuracy and a clear understanding of the total astigmatism generated by the cornea that will enable us surgeons to achieve very high quality outcomes for our patients.

Jonathan Solomon, MD, is surgical/refractive director of Solomon Eye Physicians and Surgeons in Greenbelt and Bowie, Maryland, and McLean, Virginia. He acknowledged no financial interest in the product or company mentioned herein. Dr. Solomon may be reached at jdsolomon@hotmail.com.



1. Hirschall N, Hoffmann PC, Draschl P, et al. Evaluation of factors influencing the remaining astigmatism after toric intraocular lens implantation. *J Refract Surg.* 2014;30(6):394-400.