

MicroPulse® Restores Vision in DME Patient After Multiple Ineffective Anti-VEGF Injections



Arqam Alqasem, MBBS, is Medical Director of Ishraq Eye Center in Amman, Jordan.

Although laser therapy is no longer the only treatment option for diabetic eye disease, it remains an important element in my approach to managing diabetic retinopathy and diabetic macular edema (DME). Approximately 8 months ago, our eye center in Amman, Jordan, purchased a new multifunctional laser, the IRIDEX IQ 532™. We use it to perform both conventional, continuous-wave photocoagulation and MicroPulse Laser Therapy for retinal disorders. I personally have utilized MicroPulse in the treatment of DME, macular edema related to retinal vein occlusion, and open-angle and pseudoexfoliative glaucoma. The results were encouraging from the start.

A prospective, randomized trial of patients with untreated, center-involving clinically significant DME showed MicroPulse to be as effective as standard laser in stabilizing visual acuity and reducing macular edema, with the added benefits of no tissue damage and of significant improvement in retinal sensitivity as shown by fundus autofluorescence (FAF) and micro-perimetry, respectively.¹

Further, studies using MfERG suggest that MicroPulse may preserve neural retinal functionality better than conventional laser.²

In our country's healthcare system, laser therapy is less costly than most intravitreal injections; therefore, I use MicroPulse as first-line therapy when DME is focal, as it isn't necessary to expose a patient to the risks of an anti-VEGF injection when, in my experience, the MicroPulse laser is just as effective. I also use MicroPulse as first-line therapy in cases of diffuse DME if central macular thickness (CMT) is < 300 μm. However, if DME is diffuse and CMT is > 400 μm, I prefer to begin anti-VEGF therapy to reduce CMT and improve vision as quickly as possible. This strategy is supported by the RESTORE study,³ where the laser produced results comparable to Lucentis (ranibizumab, Genentech) when CMT was < 300 μm, and ranibizumab was the best option when CMT was > 400 μm. Although these are helpful guidelines, treatment is tailored for each patient. I may recommend either anti-VEGF or MicroPulse as initial therapy for any given case including patients with diffuse DME and CMT between 300 μm and 400 μm.

I often augment anti-VEGF treatment with MicroPulse to reduce the number of anti-VEGF treatments a patient may need in the future. In the READ-2 study, patients who received laser plus Lucentis

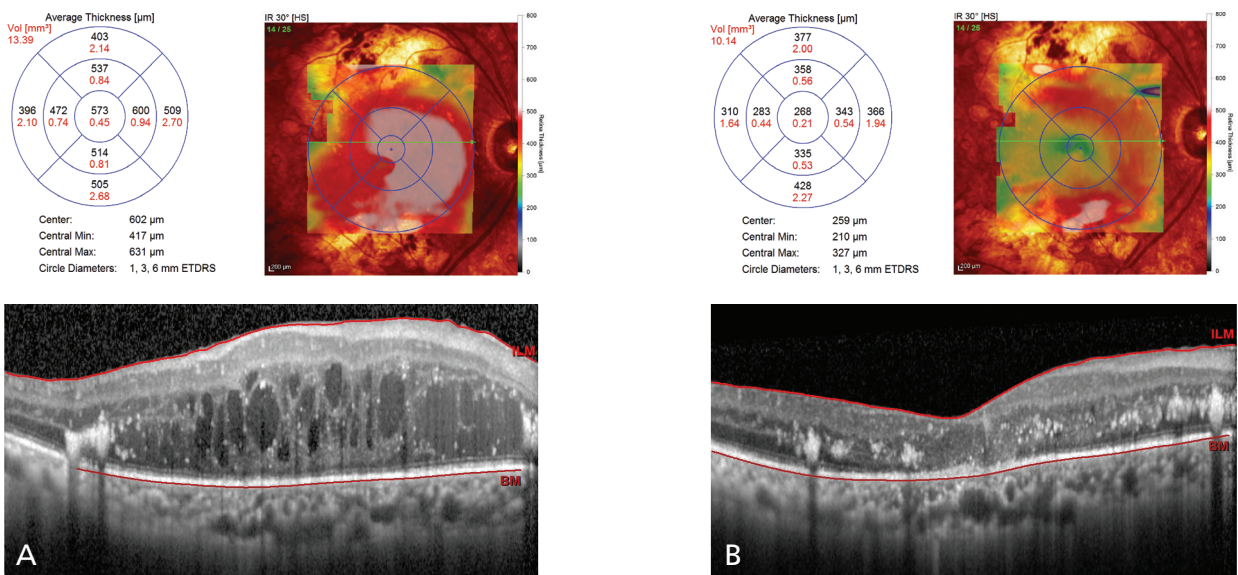


Figure 1. (A) July 27, 2015 | 1 day prior to MicroPulse | CMT 573 μm | BCVA 20/500; (B) Oct. 1, 2015 | 9 weeks post MicroPulse | CMT 268 μm | BCVA 20/80.

“In our country’s healthcare system, laser therapy is less costly than most intravitreal injections, and I use MicroPulse as first-line therapy when DME is focal ... I often augment anti-VEGF treatment with MicroPulse to maintain the effect of therapy longer, thus reducing the number of anti-VEGF treatments the patient may need in the future.”

for DME required fewer injections (4.9) compared with those who received Lucentis alone (9.3).⁴

MicroPulse is also a welcome option for DME patients who refuse intravitreal anti-VEGF injections or those for whom they’re not effective. The following patient’s recent treatment course is a good example of the latter.

PATIENT HISTORY AND TREATMENT

This patient is a 76-year-old male with a 13-year history of diabetes and insulin dependence. His hypertension is fairly well controlled with medication, and his bilateral open-angle glaucoma is controlled with topical medications. In 2011, he received aggressive bilateral pan-retinal photocoagulation for proliferative diabetic retinopathy, and in June 2012, had cataract surgery in his right eye. He is pseudophakic in both eyes.

On March 14, 2012, he presented with clinically significant macular edema OD with CMT on OCT of

576 μm and 20/400 best-corrected visual acuity (BCVA). Beginning on March 18, 2012, he was treated with three monthly Lucentis injections, which produced little to no improvement. The BCVA achieved was 20/320 following the second injection, after which time it did not improve. On March 30, 2013, CMT was 495 μm and BCVA was 20/320. One additional injection of Lucentis improved BCVA to 20/200. From that point forward until Dec. 11, 2014, he received an intravitreal injection of Avastin (bevacizumab, Genentech) plus triamcinolone acetonide and three additional Avastin injections, none of which produced any significant improvement in visual acuity. On July 27, 2015, the patient was noted to have diffuse fovea-involving DME with CMT of 573 μm and 20/500 BCVA (Figure 1A), and we scheduled a MicroPulse treatment for the next day (Table 1). When he returned for follow-up 28 days later, CMT and BCVA had both improved to 385 μm and 20/125. Both improved further by Oct. 1, 2015, to 268 μm and 20/80 (Figure 1B). At the latest follow-up visit on Dec. 2, 2015, the patient was happy with his stable 20/80 VA. I continue to observe him and would provide another MicroPulse treatment if the edema recurs.

NOTABLE ELEMENTS OF OUR TREATMENT PROTOCOL

When we purchased the IQ 532 laser, we included the TxCell™ Scanning Laser Delivery Device. This feature enhances convenience and efficiency in delivering multi-spot, high-density MicroPulse applications. In addition, since my early set of cases, I no longer use a continuous-wave test burn to determine MicroPulse treatment parameters. After detecting no evidence of retinal burns on FAF, fluorescein angiography, or OCT after MicroPulse treatment, I find a test spot to be unnecessary.

Five physicians use the IQ 532 laser at our center, and I’m certain that number will increase quickly. ■

REFERENCES

1. Vujosevic S, et al. *Retina*. 2010;30(6):908-916. 2. Venkatesh P, et al. *Photomed Laser Surg*. 2011;29;(11)727-733. 3. Schmidt-Erfurth U, Lang GE, Holz FG, et al. *Ophthalmology*. 2014;121(5):1045-1053. 4. Do DV, et al. *JAMA Ophthalmol*. 2013;131(2):139-145.



To learn more about MicroPulse, go to www.iredex.com/micropulse

Table 1. TREATMENT PARAMETERS	
IQ 532 with TxCell-guided MicroPulse for DME	
■	Wavelength: 532 nm
■	Duty cycle: 5%
■	Spot size on slit lamp adapter: 200 μm
■	Contact lens: Volk HR Centralis
■	Exposure duration: 200 ms
■	Power: 400 mW
■	TxCell-guided MicroPulse delivery: High-density, zero-spacing application of 588 spots using a 7x7 treatment grid to cover the entire edematous area based on OCT, including the fovea

Treatment techniques and opinions presented in this case report are those of the author. IRIDEX lasers are cleared for retinal photocoagulation of vascular and structural abnormalities of the retina and choroid; and iridotomy, iridectomy and trabeculoplasty in angle-closure glaucoma and open-angle glaucoma. IRIDEX assumes no responsibility for patient treatment and outcome. IRIDEX, IRIDEX logo, and MicroPulse are registered trademarks, and IQ 577 and TxCell are trademarks of IRIDEX Corporation.

IRIDEX | 1212 Terra Bella Avenue | Mountain View, CA 94043 | 800.388.4747 (U.S. inquiries) | info@iredex.com (U.S. & int'l inquiries) | www.iredex.com

© 2016 IRIDEX Corporation. All rights reserved. LT0633